

Hypermobility 114: Hospitalization with HSD, POTS, MCAD

Leslie N Russek, PT, DPT, PhD, OCS
Clarkson University



Who Am I?

- Professor Emeritus, Physical Therapy Department, Clarkson University
- Retired PT, St. Lawrence Health System, Potsdam NY
 - Clinical specialties: hypermobility, fibromyalgia, headaches, temporomandibular disorders
- Member: Ehlers-Danlos Society Medical and Scientific Board
- Chair: The Allied Health Working Group of the International Consortium of Ehlers-Danlos Syndromes and Hypermobility Spectrum Disorders
- Frequent presenter to professional and patient groups at national and international conferences
- Author of multiple review and research articles on hypermobility
- Author: “Pain Mechanisms in HSD” in Di Bon, *The Integral Movement Method for Hypermobility Management*
- Author: “Chronic Pain” chapter in *Physical Rehabilitation* textbook for PT students
- Lrussek@Clarkson.edu
- <https://webpace.clarkson.edu/~lrussek/>

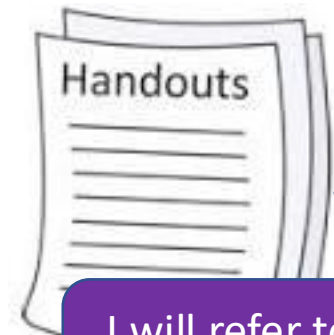
**I do not have any
conflicts of interest to report**

Hypermobility Lecture Series Schedule

- HSD 101: Basics of HSD/hEDS and self-care
- HSD 102: POTS and POTS self-care, basics of MCAS
- HSD 103: Pain management in HSD/hEDS
- HSD 104: Safe exercise selection and progression with HSD/hEDS
- HSD 104b: How to modify exercises so they work for you
- HSD 105: Posture and joint protection
- HSD 106: Gut issues in HSD/hEDS, POTS, MCAS
- HSD 107: Fatigue in HSD/hEDS and POTS
- HSD 108: Headaches, migraines, & TMJ pain associated with HSD, POTS and MCAS
- HSD 109: Breathing disorders in HSD
- HSD 110: Lumbar instability
- HSD 111: Conservative management of cervical instability
- HSD 112: The vagus nerve
- HSD 113: The role of fascia
- HSD 114: Hospitalization with HSD, POTS, MCAD
- HSD 115: Functional Neurological Disorder (FND)
- HSD 115: Bleeding Disorders in HSD

I will refer to these if you want more info





I will refer to these if you want more info

Relevant Handouts Available

- <https://webpace.clarkson.edu/~lrussek/research.html>
- [Surgical precautions for people with HSD/hEDS](#). Most of the info in today's session. This is fairly technical and perhaps best for health care providers
- [Chronic Pain Partners surgical planning booklet](#). Excellent patient information for EDS patients preparing for surgery
- **POTS**
 - [Overview of POTS symptoms and causes](#).
 - [Checklist for POTS self-care management](#).
- **MCAS**
 - [Suggestions for managing MCAS](#).
 - [How to check your medications for \(MCAS\) sensitivities](#).
 - [MCAS in the Emergency Room](#). (not created by me)



Disclaimers

The information in this presentation is for general purposes, only, and may or may not apply to your situation.

This presentation is based on published medical literature, but cannot be used to diagnose or treat individual patients.

This information is best used to start a discussion with your health care providers to determine if/how any of these concerns may apply to you.

I cannot diagnose or make specific treatment recommendations in this lecture.

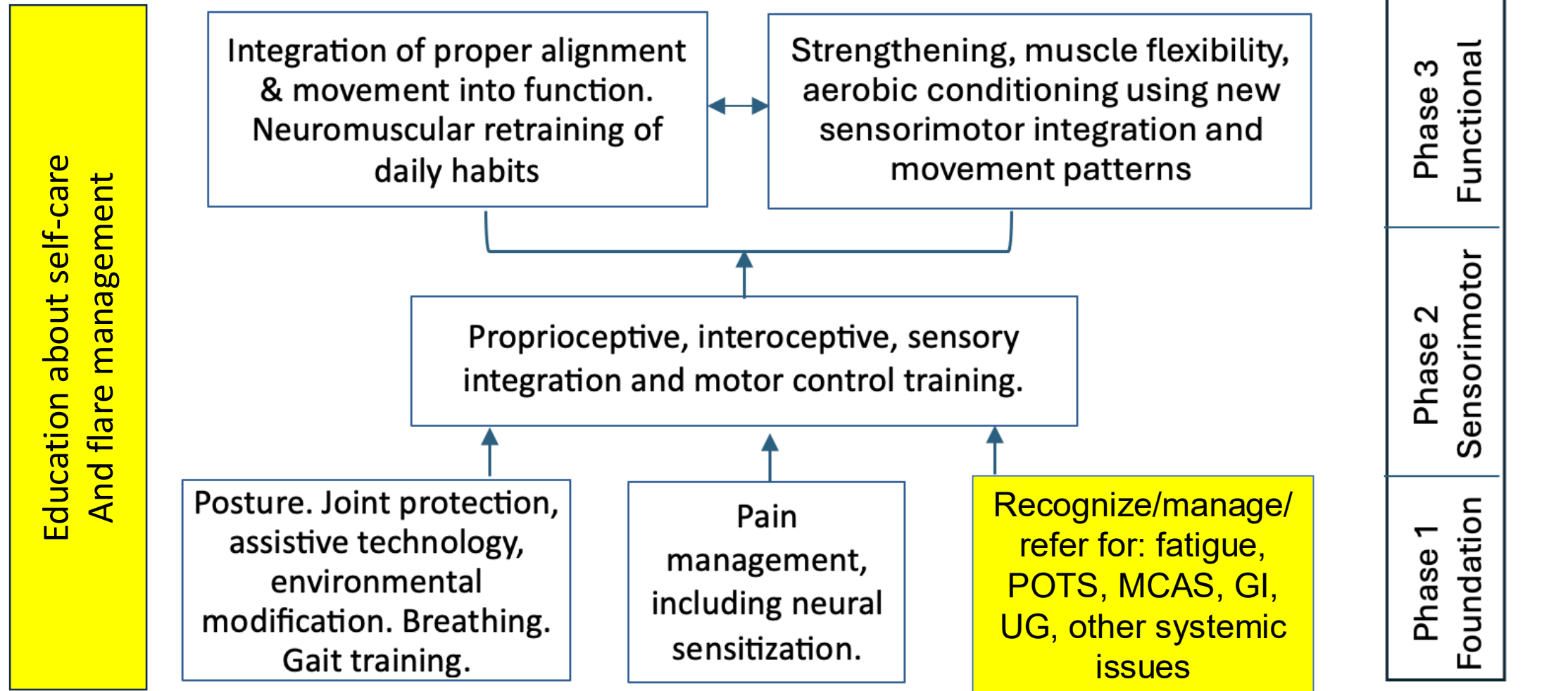


Objectives

By the end of this session, participants should be able to:


1. Identify concerns that can arise in the hospital for patients with HSD, POTS, or MCAD.
 2. Begin a discussion with healthcare providers about medical concerns due to HSD, POTS or MCAD.
 3. Discuss surgical precautions with providers
- HSD: Hypermobility Spectrum Disorders and hypermobile Ehlers-Danlos Syndrome
 - POTS: Postural Orthostatic Tachycardia Syndrome, in this presentation including other forms of dysautonomia, such as orthostatic intolerance
 - MCAD: Mast Cell Activation Disorders

PT Approach to Managing HSD



Outline

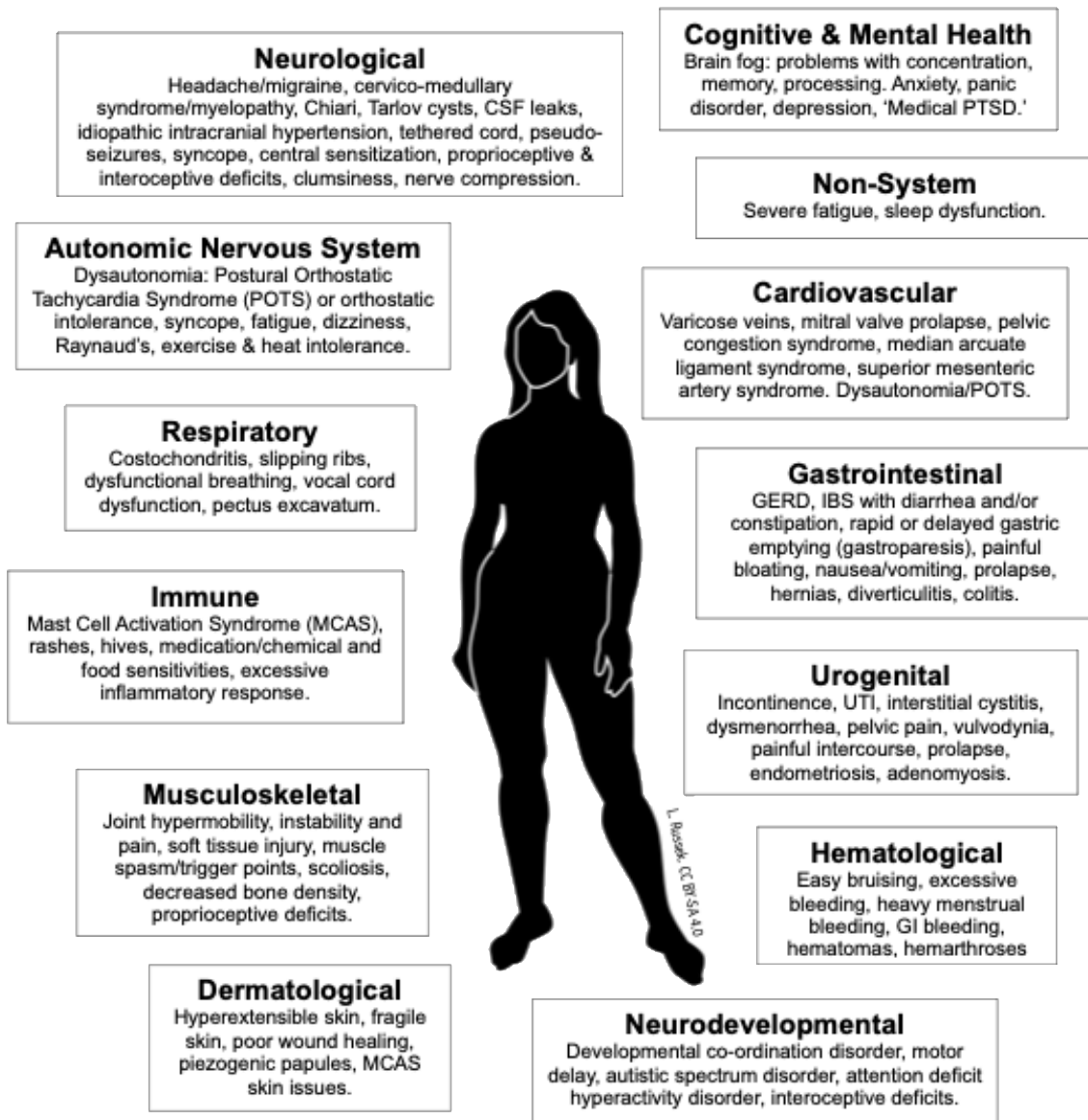
- Why is it important to know about HSD, POTS, MCAD in the hospital?
- When should you suspect HSD, POTS, MCAD?
- Emergency room issues
- Specific conditions and systems
- Surgical precautions
- Resources for you and your providers



Recognizing Signs and Symptoms

- It can be helpful to recognize what signs & symptoms might be due to HSD, POTS, or MCAS
- You may be able to avoid unnecessary testing
- It may suggest appropriate treatment approaches
 - For example:
 - A migraine due to POTS may resolve with an IV saline drip
 - A migraine due to MCAS may resolve with appropriate antihistamine medication
 - A migraine due to cervical instability may require a neck brace to decrease stress to the brainstem
- It can reduce the chance that your symptoms are considered psychogenic (due to psychological causes and not physical)

COMMON SYMPTOMS OF HYPERMOBILITY SPECTRUM DISORDERS




Hypermobility: HSD

Intro to HSD

HSD101:
Intro to HSD

When to suspect HSD flare:

- Multiple body parts flare at once or something isn't healing at the rate it should
- Multiple body systems flare at once
- MCAS flare that may be triggering HSD flare



HSD: Why Does It Matter?

Patients:

- May have multiple issues that need to be addressed.
- May have inappropriate testing done or diagnoses missed.
- May have trouble using assistive devices (e.g., crutches, walker) due to unrelated joint problems.
- Are at greater risk of falling due to both physical & cognitive issues.
- May be slow to process information or trouble following instructions due to brain-fog. May appear to be uncooperative.
- Are likely to be overwhelmed and anxious due to sensory overload.

Family

- Family stress and dysfunction if Sx perceived as psychosomatic.
- Frequent injuries in children may look like child abuse.

Dysautonomia (especially POTS)

About POTS

HSD 102: POTS & MCAD/MCAS

PUPILOMOTOR

impaired pupil response
(uncomfortable in bright light)
difficulty with vision



NEUROLOGICAL

migraine, cognitive deficits, brain fog & mental clouding

SECRETOMOTOR

difficulty sweating, tearing and other fluid production (dry eyes, dry mouth, difficulty swallowing, dry skin)

PULMONARY

shortness of breath
easily winded
difficulty breathing

GASTROINTESTINAL

nausea, vomiting, diarrhea, constipation, abdominal pain, reflux, heartburn, impaired motility

CARDIOVASCULAR

palpitations, chest discomfort
high heart rate (tachycardia)
low heart rate (bradycardia)
high or low blood pressure
abnormal blood vessel functioning
blood pooling

URINARY

difficulty with urine retention and/or excretion

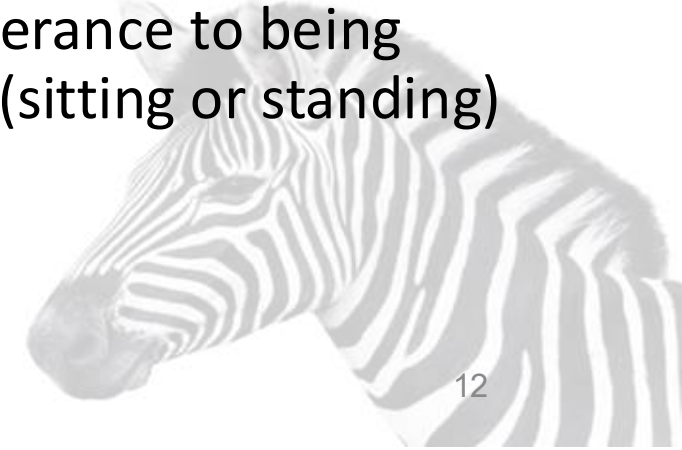ORTHOSTATIC INTOLERANCE

difficulty standing still, fatigue, lightheadedness, increase in symptoms with upright posture, fainting (syncope) or near-fainting, pallor

Symptoms can be **SUDDEN** and **unpredictable** in onset

Also

- Presyncope (almost fainting) and syncope (fainting)
- Syncopal seizures (“pseudo-seizures”)
- Severe fatigue and exercise intolerance
- Poor tolerance to being upright (sitting or standing)



Dysautonomia: Why Does It Matter?

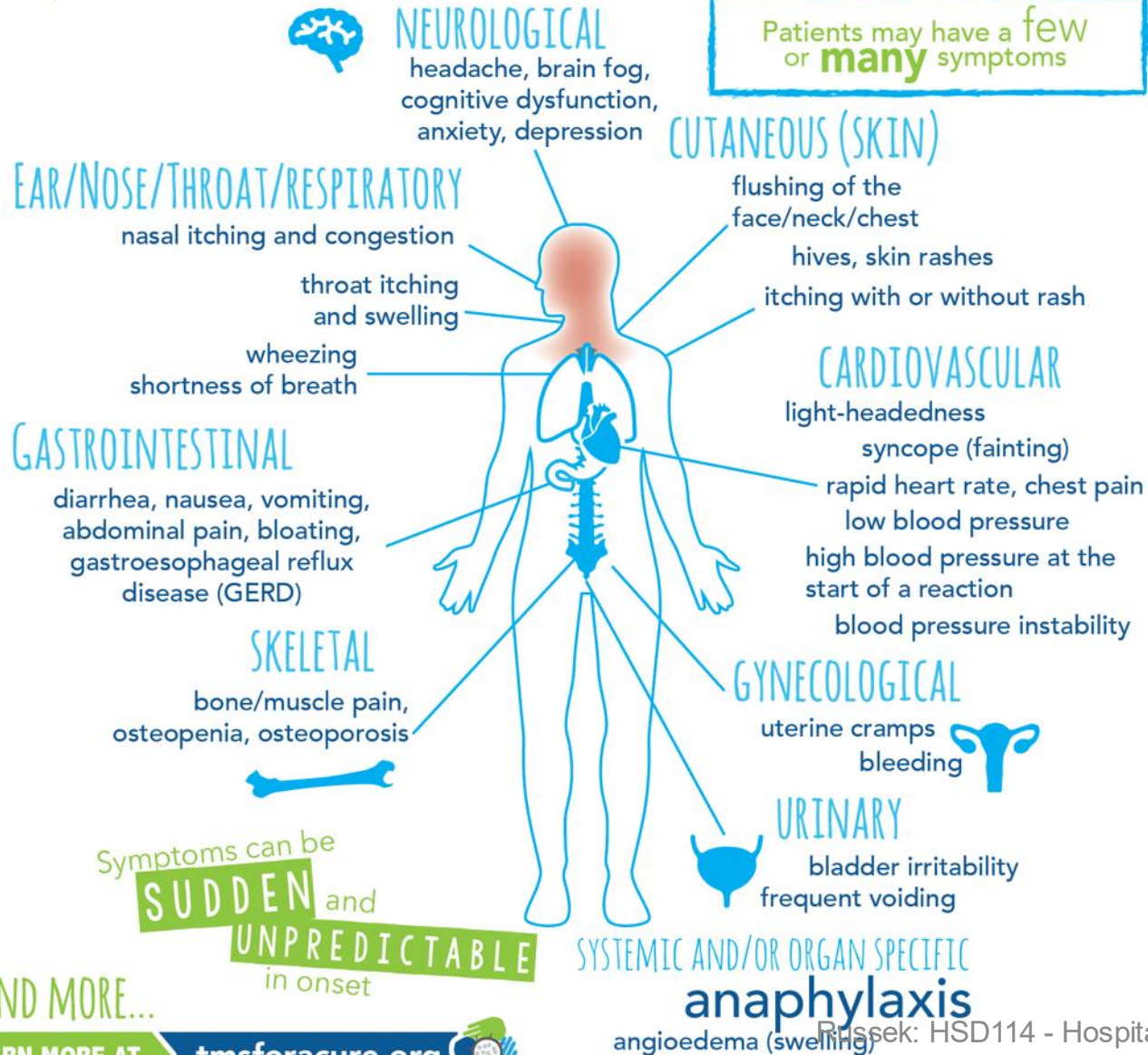
- Inappropriate assessments and incorrect diagnoses;
 - Inability to accurately assess the risks and benefits associated with medical procedures and medications;
 - Inappropriate medical interventions;
 - Family stress and dysfunction if Sx perceived as psychosomatic.
 - Failure to recognize severity of fatigue or orthostatic intolerance limiting function or exercise tolerance
 - Mistrust of healthcare providers and negative expectations for future health care encounters (Stiles, 2018)
- Patient might not tolerate upright activity
- Increased risk of falls due to dizziness
- Patient might benefit from extra hydration/IV, compression, pacing



Some common **SYMPTOMS**
of MAST CELL DISEASE
that are caused by mast cell mediator release

HSD 102: POTS & MCAD/MCAS

Patients may have a few or **many** symptoms




Also:

- Migraines
- Intolerance to medicines “that no-one ever reacts to”
- Smell sensitivity to perfumes or chemicals
- Food intolerance
- Adhesive sensitivity



MCAS: Why Does It Matter?

- Incorrect diagnosis can lead to:
 - Inappropriate or unnecessary medical testing
 - Difficulty assessing risk and benefit of interventions
 - Anaphylactic reactions to medications or environmental triggers
 - Patients may be triggered by smells and chemicals, including provider scented personal care products
 - We may miss the underlying driving force causing other problems
- (Afrin, 2021)*
- Treatment needs to address underlying inflammation & MCAS triggers
 - Patients may tolerate less activity
 - Brain-fog can increase risk of falls, interfere with pt's ability to follow instructions



Common Emergency Room Conditions

- Severe migraines due to MCAD, POTS, HSD
- Non-epileptic seizures or fainting due to cervical instability or POTS
- Anxiety or panic attacks due to POTS, MCAD, HSD
- Chest pain due to HSD or POTS
- Anaphylactic reactions due to MCAD
- Difficulty having blood drawn or IV set



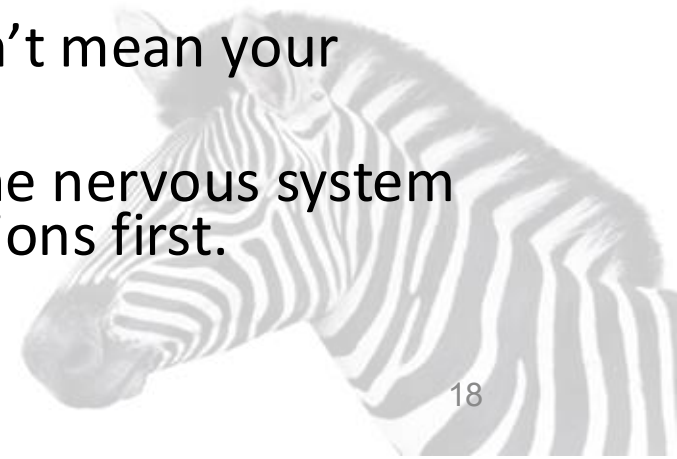Migraines and Headaches



- Migraines are very common in POTS and MCAD flares. (Wig, 2019, Conti, 2019)
 - Are you experiencing an MCAD flare? (GI, skin, breathing, allergy symptoms?)
 - Have you been exposed to anything that could trigger MCAD?
 - E.g.: chemicals, new medications, foods, smoke, perfumes etc.
 - Are you experiencing a POTS flare? (lightheaded, tachycardia, anxious?)
 - Any reason why your POTS might flare?
 - E.g., heat, dehydration, MCAD flare, cervical instability, etc.
- Cervical instability can trigger migraines and headaches (Henderson, 2017)
 - Have you been in positions or activities that would stress the neck?
 - E.g., washing hair, dental work, car-rides, prolonged leaning forward, etc.
- Do you have any other new or worse neurological signs or symptoms?
 - Seizures, dystonia (uncontrolled muscle spasticity), passing out, numbness or tingling, vision changes, voice changes
 - Do you have sudden headaches with position changes, such as lying down?

Neurological Signs & Symptoms

- Pseudo seizures/non-epileptic seizures, fainting and dystonia (muscle spasticity) may be due to cervical instability. (Russek, 2022)
 - Cervical instability may be aggravated by an MCAD flare
 - MRI done with you lying down and the neck in neutral cannot diagnose cervical instability
- Fainting caused by POTS-related syncopal events can mimic seizures, especially when they include myoclonic jerking (spastic twitching of muscles). (Rugg-Gunn, 2009)
- People with HSD are more vulnerable to a variety of neurological conditions:
 - Craniocervical and atlantoaxial instability (CCI and AAI), Chiari I malformation, CSF (cerebrospinal fluid) leaks, idiopathic intracranial hypertension, Eagle syndrome, tethered cord and Tarlov cysts. (Henderson, 2017)
- You may be anxious because of these symptoms, but this doesn't mean your symptoms are caused by anxiety
- Functional Neurological Disorders (FND) is a condition where the nervous system malfunctions. FND can exist in HSD, but look for other explanations first.



Cardiovascular Signs & Symptoms



- Dysautonomia can lead to orthostatic intolerance. HR may be abnormally high or blood pressure may drop (orthostatic hypotension). Dysautonomia can be aggravated by: bedrest, surgery, anesthesia, COVID. It most commonly presents in adolescent and adult women. (Vernino, 2021, Raj, 2020)
- Chest pain:
 - Costochondritis is common because the joints between ribs and sternum can be lax. Costochondritis symptoms mimic a heart attack. (<https://www.ncbi.nlm.nih.gov/books/NBK532931/>)
 - Subluxed ribs may also cause crushing chest pain that may feel like a heart attack.
 - Pectoralis and scalene trigger points caused by excessive chest breathing pattern can also sometimes feel like a heart attack. (Bagcier, 2020)
- Pectus excavatum (inward pointing breastbone) can restrict space for the heart to expand and restrict rib movement, leading to palpitations that are worse lying down. (Tocchioni, 2013)

Difficulty Having Blood Drawn/IV Set

- Many people with EDS and POTS report difficulty when medical providers draw blood or set IV lines
 - Trouble finding veins,
 - Rolling veins, getting needles into the veins
 - Severe bruising afterwards
- This is worse if you are dehydrated because you have been told to stop drinking fluids for a procedure
- Ask if you do have to stop drinking water for hours before your procedure
- Drink plenty of fluids immediately before the draw
 - Fluids without electrolytes won't be absorbed as well

This is anecdotal – I hear it a lot, but cannot find any good medical evidence



Anaphylaxis Associated with MCAD

Anaphylaxis and Mast Cell Disease

Anaphylaxis is an acute, life-threatening, systemic reaction that results from the sudden, rapid, systemic release of mediators from mast cells and basophils. Anaphylaxis symptoms present as new or worsening symptoms including:

- Mouth: itching, swelling of lips and/or tongue
- Throat: itching, tightness, closure, hoarseness
- Skin: itching, hives, redness, swelling, flushing
- Gut: nausea, vomiting, diarrhea, cramps
- Lung: shortness of breath, cough, wheeze
- Heart: weak pulse, dizziness, passing out

- Symptoms of anaphylaxis: <https://tmsforacure.org/anaphylaxis/>
- ER MCAD crisis response plan: medications to avoid or use: https://tmsforacure.org/wp-content/uploads/2023/06/TMS_ER-Protocol-2022_fillable.pdf

Russek: HSD114 - Hospitalization

Anaphylaxis in a Patient with Mast Cell Disease

*Please note: These recommendations may differ from general guidelines for anaphylaxis in that they may include additional considerations specific for the Mast Cell Disease patient.

PLACE PATIENT IN RECUMBENT POSITION AND ADMINISTER

(Please check all that apply)

- Epinephrine** 0.3 mL of 1:1000 IM (auto injector preferred*). Repeat 3x at 5-minute intervals if blood pressure <90 systolic
- Oxygen** by mask or nasal cannula
- If trigger is present, remove trigger from the reaction if possible
- Benadryl** (Generic: diphenhydramine) 25–50 mg intravenously (**slow IV push**) every 2–4 hours, or **cetirizine** 10 mg intravenously, or **Hydroxyzine Hydrochloride** 25 mg intramuscular dose every 2–4 hours
- IV Fluids** 1–2 L of Normal Saline until SBP is >90
- Albuterol** by nebulization / Alternatively, Racemic Epinephrine can be given by nebulization
- Solu-Medrol** (Generic: methylprednisolone) 0.5–1 mg/kg X1 and repeat 1–2 hours later if SBP below 90
- Glucagon**™ for patients on beta-blockers who do not respond to Epinephrine or who have cardiac disease that make continued boluses/treatment of Epinephrine contraindicated
- Optional:** Prednisone 1mg/kg orally

MCAS Crisis Medications



Medications to Use and Avoid Quick Reference Guide

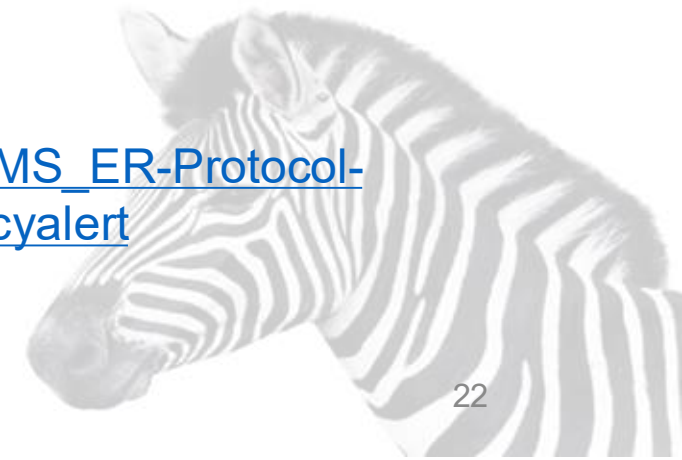Medications to avoid or use with caution in patients with mast cell disease in emergency situations

Please note: Some of the Medications to Avoid may be given if absolutely necessary, if given with a prep to stabilize mast cells. Please refer to one of our mast cell experts for instructions.

Medication Type	Avoid or Use With Caution	Medications That Are Typically Tolerated
General Medications	<ul style="list-style-type: none"> alcohol amphotericin b dextran dextromethorphan polymyxin B quinine vancomycin IV alpha-adrenergic blockers beta-adrenergic blockers 	<ul style="list-style-type: none"> calcium channel blockers centrally acting alpha 2 adrenergic stimulants aldosterone antagonists Oral doses of Vancomycin may be tolerated in some cases.
Pain Medications	<ul style="list-style-type: none"> opioid narcotics (may be tolerated by some individuals) Toradol (ketorolac) Non-steroidal anti-inflammatory drugs (unless the patient is already taking a drug from this class) 	<ul style="list-style-type: none"> fentanyl [may require adjunct treatment with Zofran (ondansetron)] tramadol

General Anesthetics	<ul style="list-style-type: none"> atracurium doxacurium rocuronium mivacurium 	<ul style="list-style-type: none"> pancuronium vecuronium
Local Anesthetics	<ul style="list-style-type: none"> benzocaine chloroprocaine procaine tetracaine 	<ul style="list-style-type: none"> bupivacaine lidocaine mepivacaine prilocaine levobupivacaine ropivacaine
Intraoperative Induction Medications		<ul style="list-style-type: none"> ketamine midazolam propofol
Inhaled Anesthetics		<ul style="list-style-type: none"> sevoflurane

https://tmsforcure.org/wp-content/uploads/2023/06/TMS_ER-Protocol-2022_fillable.pdf#emergencyalert





Questions?



Hospitalization

- Specific conditions and systems
 - Musculoskeletal issues
 - Neurological issues
 - Bleeding issues
 - Immune system issues, MCAD
 - Skin issues
 - Cardiovascular issues
 - Respiratory Issues
 - Obstetric issues



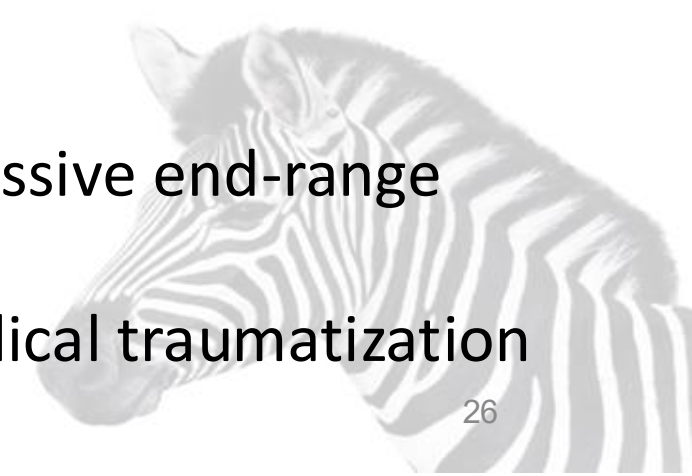Musculoskeletal Issues

- Trauma that might not be sufficient to cause injury in a non-hypermobile person may cause injury in HSD/hEDS. For example, a patient may sublux or dislocate a joint rolling over in bed or sneezing. Non-traumatic dislocations and subluxations are common and can be very painful, even if the joint has relocated. (HSD) (Wiesmann, 2014)
- Joints become more unstable as bedrest deconditions muscles that normally provide support. Patients may report hips, shoulders or ribs 'slipping out' or other sharp pain associated with subluxations. (HSD)
- Subluxed ribs may cause crushing chest pain that may feel like a heart attack. (HSD)
- MCAS can increase generalized inflammation, increasing severity/pain.(MCAS)



Musculoskeletal Issues: How Could This Impact PT?

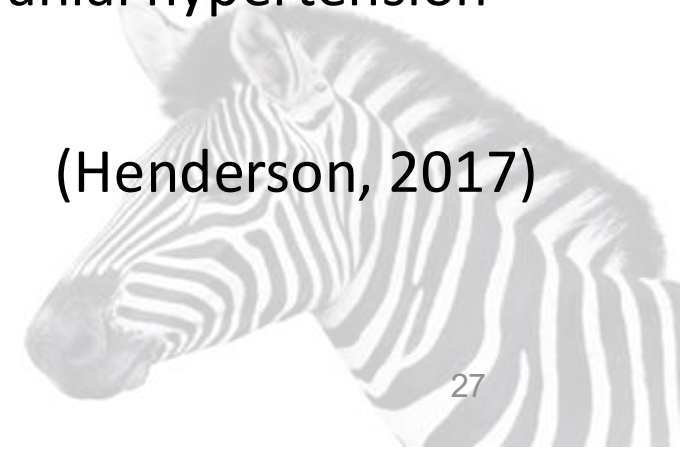- Excessive pain, weakness, fatigue, joint instability, poor proprioceptive or interoceptive awareness
 - Patient may have pre-existing chronic pain, and have excessive pain due to acute or acute on chronic pain.
- Functional challenges:
 - Difficulty responding to verbal cueing/multi-step demands with physical movements
 - Difficulty doing transfers or using assistive devices due to:
 - Weakness,
 - Joint instability,
 - Difficulty with sequencing and coordinating movements
- Ergonomics: need for more positional support to avoid excessive end-range positioning
- Psychological issues: brain-fog, fear avoidance, anxiety, medical traumatization



Central Neurological System Problems

- Signs & Symptoms:
 - Vision/hearing changes
 - Sensory changes
 - Weakness/loss of coordination
 - Tics, tremors or jerks
 - Balance disturbance
 - Speech problems (dysphagia)
 - Nausea/vomiting
 - Non-epileptic seizures
 - Syncope (fainting)
 - Bowel/bladder dysfunction
 - Depersonalization (feeling unreal, disconnected from your body)
- Possible neuro conditions:
 - Upper cervical instability
 - Chiari malformation
 - Tethered cord
 - Cerebrospinal fluid leak
 - Tarlov cysts
 - Idiopathic intracranial hypertension
 - Arachnoiditis

(Henderson, 2017)



Bleeding Issues

- Excessive bleeding is more common in people with hEDS. This includes bleeding skin, bruising, heavy menstrual bleeding, hematoma formation, bleeding from the gums, nosebleeds, and excessive bleeding during surgery or childbirth.
- 62% of patients with HSD had abnormal bleeding (ISTH-BAT) scores indicating bleeding disorders and high risk of bleeding complications.
- In children with HSD, 75% had abnormal Bleeding Assessment Tool (BAT), but only 12.3% had been assessed for bleeding.
- **80% of female patients seen in a BDUC clinic are hypermobile.** (Sanchez-Raya, 2018)
- Women with heavy menstrual bleeding should be screened for bleeding disorders.
- Patients with hEDS/HSD are more likely to have negative Von Willebrand Disease and hemophilia tests in spite of having a bleeding disorder – hence the bleeding disorder might not be recognized/acknowledged.

Wiesmann, 2014; Kumskova, 2023; Wright, 2023; Kendel, 2023

Bleeding Issues: Why Do We Care?

- Ways it may impact assessment or treatment
 - Patients may have excessive bleeding in response to injury, surgery, childbirth, dental work
 - Bleeding may become life-threatening
 - Strategies to manage bleeding may vary depending on contributing factors
 - May need additional hydration if patient losing blood
 - Heavy menstrual bleeding should be managed as a bleeding disorder rather than just an OB/GYN issues



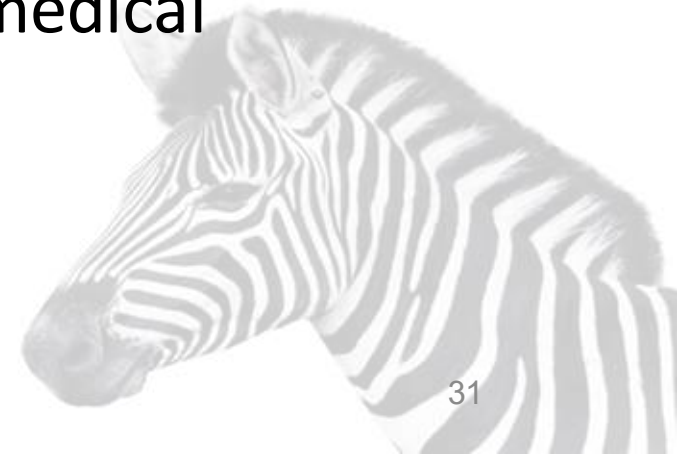
Skin Issues

- Fragile skin requires specialized procedures for suturing.(HSD)^(Castori, 2012)
- Fragile skin can lead to skin breakdown more quickly than in non-hypermobility patients.(HSD)^(Doolan, 2023)
- Skin can be more easily damaged by tape (including EKG pads, tape used to stabilize IV needles. Skin is also vulnerable to abrasion.^(Doolan, 2023)
- Mast cell activation disorder (MCAD) can lead to severe tape/adhesive allergies, including to EKG electrodes.^(Mihele, 2023) (MCAD)



Skin Issues: Why Do We Care?

- Wound/sutures may heal more slowly, need to monitor wound healing more closely
- Monitor for reactions to tape, modify taping procedures
 - Remove tape more cautiously due to skin fragility
- Hand placement during manual treatments or contact exercises
- Transfers (e.g., in/out of bed) need to avoid excessive skin pulling: abrasion
- Monitor for skin abrasion from sheets, splints, casting, medical devices
- Monitor for skin reactions to chemicals, detergents, etc.



Immune Sensitivity

- Medication sensitivity and reactions to medications that are usually well tolerated. People tend to be sensitive to excipients in the medication (not the active ingredient); dyes and alcohol preservatives are common problems. (Schofield, 2019)
- The web site <https://dailymed.nlm.nih.gov/dailymed/> provides useful info about excipients. Patients with MCAD may report being “allergic” to many medications. While this might not be a true allergy, not tolerate many medications. (MCAD)
- Intolerance to smells, including perfume, cologne, chemical cleaners. In patients with odor sensitivity, the room and all providers who enter the room need to be fragrance free. Exposure to smells may trigger migraines or cardiac irregularities. (MCAD)

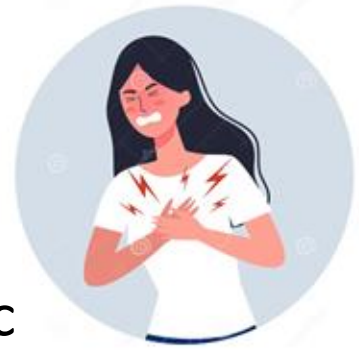

Immune Issues: Why Do We Care?

- Patients may have allergic reaction to many things: scented body care products on care providers, chemical cleaners, laundry detergents, medical devices and adhesives.
- Frequent medication sensitivity & intolerance, even meds that are typically tolerated well.
- Frequent food intolerances might not be recognized/addressed in hospital.
- Any interruption in MCAS medications can cause severe flare
- MCAS can cause widespread and systemic inflammation and exacerbate any other issues, including pain sensitization.
- Diarrhea or vomiting can compromise ability to engage in rehab.
- MCAS can flare POTS or HSD.
- Brain fog can interfere with ability to follow instructions.



Cardiovascular Signs & Symptoms



- Dysautonomia can lead to orthostatic intolerance. Tachycardia or orthostatic hypotension.

- Dysautonomia can be triggered by bedrest, surgery, anesthesia, COVID.
- Withholding fluids prior to surgery will trigger flare,

(Clarke, 2022Vernino, 2021, Raj, 2020)

- Chest pain:

- Costochondritis common due to sternocostal instability. Costochondritis symptoms mimic a heart attack. (Schumann, 2025)
- Subluxed ribs may also cause crushing chest pain that may feel like a heart attack. (Bascom, 2021)
- Pectoralis and scalene trigger points caused by excessive chest breathing pattern can also sometimes feel like a heart attack. (Bagcier, 2020)

- Pectus excavatum can restrict space for the heart to expand and restrict rib movement, leading to palpitations that are worse lying down. (Tocchioni, 2013)
- Risk of aortic dilation (aortic rupture in vascular EDS) (Ritter, 2017)

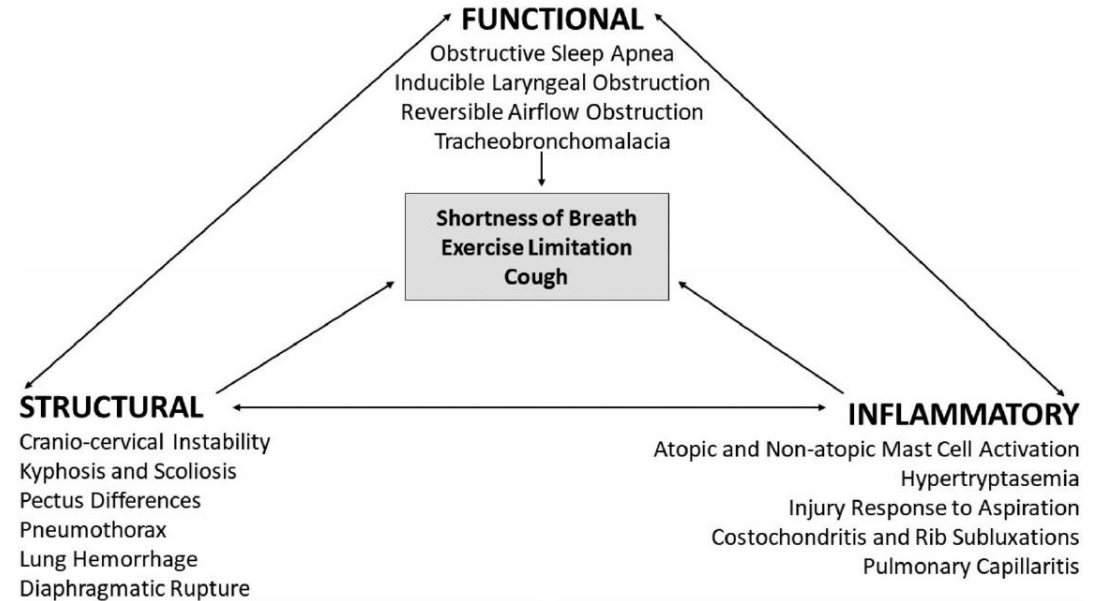
Cardiac Issues: Why Do We Care?

- Avoid misdiagnosis.
- Patients may have excessive **weakness, fatigue**
- **Diaphragmatic breathing assessment and education essential**
 - **Assess or manage rib subluxation or costochondritis, or recommend Rx after discharge**
- Psychological issues: **brain-fog, anxiety**, fear avoidance/anxiety, medical traumatization



Respiratory Issues

- An acute POTS attack may present with difficulty breathing. (POTS)
- MCAD reactions causing sinus congestion can lead to increased mouth breathing. Mouth breathing contributes to TMJ pain, headaches, tinnitus.
- Pectus excavatum (inward pointing breastbone) can restrict space for lungs to expand, and can restrict rib movement. (Tocchioni, 2013)



Bascom R, Dhingra R, Francomano CA. Respiratory manifestations in the Ehlers-Danlos syndromes. *Am J Med Genet C Semin Med Genet*. Dec 2021;187(4):533-548. doi:10.1002/ajmg.c.31953



Obstetric Issues

- Complications with delivery appear to be more common in HSD/hEDS. This includes uterine torsion, cervical incompetence, preterm labor, severe perineal tearing, and failure of sutures for episiotomies and C-sections. Separation of the pubic symphysis and coccyx dislocation may also occur. (Gilliam, 2020)
- MCAS issues may also complicate pregnancy. (Dorff, 2019)
- Recent publication:
 - Management of childbearing with hypermobile Ehlers-Danlos syndrome and hypermobility spectrum disorders: A scoping review and expert co-creation of evidence-based clinical guidelines (Pezaro, 2024)
 - Includes a 'what to do' table for common problems
 - <https://journals.plos.org/plosone/article?id=10.1371/journal.pone.0302401>

Surgical Risks & Issues

- Surgical risks
 - Cervical instability
 - Joint dislocation
 - Anesthesia reaction
 - Cardiovascular instability
 - Excessive bleeding
 - Skin fragility



Surgical Precautions

- Orthopedic surgery is only effective 34% of the time in patients with hEDS; this is 50% as often as non-hypermobile pts. Therefore, it is important that conservative management (with an hEDS knowledgeable provider) be fully explored before resorting to surgery.
- Orthopedic and spinal surgeries in hEDS are more likely to have complications, with one study reporting 91% complication rate in orthopedic surgeries.
- Gastrointestinal surgeries in hEDS are more likely to have complications, but fewer complications than vascular EDS. Typical complications include tissue perforation or tears, recurrent hernias or increased bleeding.
- Surgeons should take hEDS into account when planning surgery.

Rombaut, 2011; Yonko, 2021; Homere, 2020; Chi, 2023; Kulas Søborg, 2017; Burcharth, 2012)



Surgical Issues Related to Positioning

- Patients with possible cervical instability require careful neck positioning during surgery, especially in cases of intubation. In some cases, use of a rigid cervical collar during surgery is a wise precaution. (Castori, 2012)
- Intubation may cause subluxation of the temporomandibular joint or damage to the disc. (Wiesmann, 2014)
- Joints and tissues not being operated on may be stressed or damaged by positioning. For example, shoulder hyperabduction may cause a brachial plexus injury. (Wiesmann, 2014)


Surgical Issues: Tissue Fragility

- Shear forces may damage skin, for example when rolling or transferring patients. Gripping patients for rolling or transferring may cause bruises.
- Tissue healing is delayed; therefore recovery is slower and rehab may need to proceed slower.
- Intubation may cause damage to fragile tracheal mucosa. A smaller endotracheal tubes may be less damaging.
- There is increased risk of bleeding due to vascular fragility. See Wiesmann, 2014, for extensive discussion of operative bleeding.
- Tourniquets may cause bruising and hematoma formation.
- Any surgery with devices moved within the body (laparoscopy, colonoscopy, etc.) have increased chance of damaging tissues.
- Special procedures recommended for skin sutures: closer together, leave sutures in longer.
- **Delayed tissue healing lead to slower recovery; rehab may need to proceed slower.**

(Clarke, 2022; Wiesmann, 2014; Ericson, 2017; Burcharth, 2012; Castori, 2012)

Summary: Surgical Precautions: HSD

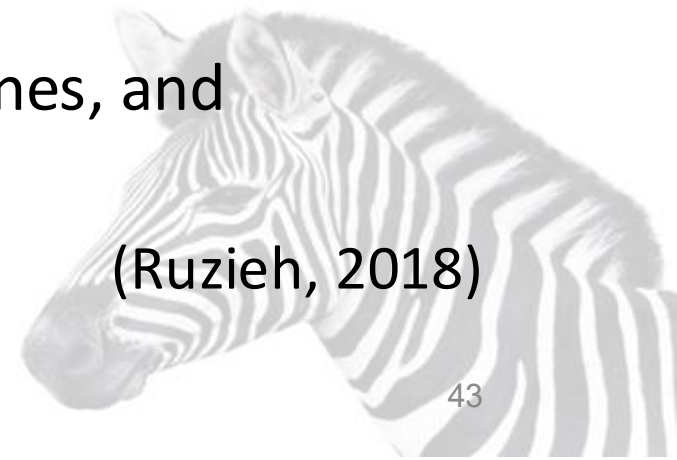- Uninvolved joints and tissues may be fragile and could be damaged by positioning or transfers.
- Tissues are fragile and can be damaged by unintended stresses, are likely to be more damaged by surgical procedures, and are likely to heal more poorly.
- Excessive bleeding may be a complication.



Surgical Precautions due to POTS

- Orthostatic intolerance (e.g. POTS) may lead to abnormal response to anesthesia.
- Orthostatic intolerance may result in poor regulation of blood pressure after surgery, interfering with getting patient upright after surgery; this may interfere with physical therapy. Since anesthesia can cause POTS flares, the patient may be more POTS-reactive after surgery than before.
- Consider increased hydration before and after surgery.
- Use hypotensive agents, sympathomimetics, catecholamines, and vasodilators with caution. Use sedating drugs sparingly.

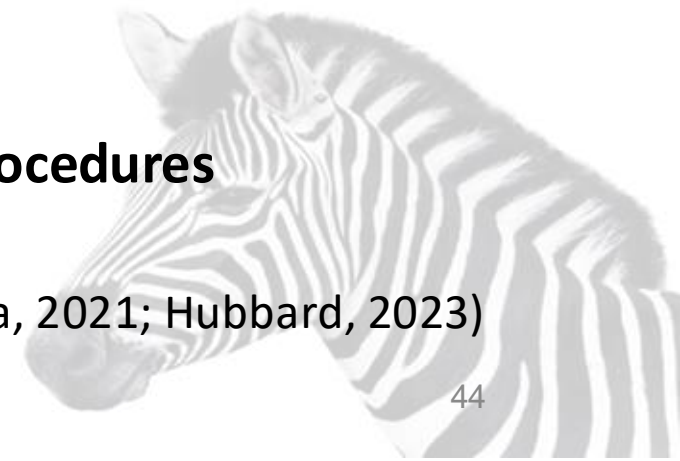
(Ruzieh, 2018)



Surgical Precautions due to MCAD

- Reactions to medications
 - Local anesthetics: benzocaine, procaine, chlorprocaine, tetracaine
 - Anti-infectives: Vancomycine IV, fluoroquinolones, amphotericin B, polymyxin B
 - Opioid analgesics: morphine, codeine, meperidine
 - NSAIDS: ibuprofen, naproxen
 - Protamine
- Increased reactivity if MCAD medications were discontinued for surgery.
- Reactions to adhesives in tape, EKG pads, etc
- Environmental triggers:
 - External: contrast media/dyes, chemical odors, chlorhexidine, latex, blood transfusions, mechanical friction, temperature extremes
- Internal triggers: stress, infection, pain
- **Excessive inflammatory reactions may limit tolerance to medical procedures**

(Lacerna, 2021; Hubbard, 2023)



Summary

- There are lots of reasons why people with HSD/hEDS, POTS and MCAD may present with medical issues that require treatment in the hospital.
- People with the Trifecta sometimes present or respond differently.
- Discuss HSD, POTS, MCAD with providers when planning for surgery.
- Be aware of special issues you may need when receiving emergency care.
- Communicate with your care providers if you have HSD/hEDS, POTS, or MCAD.
- There are some excellent resources for you and your provider.

Patient Resources For HSD/hEDS

- “Meeting Your EDS Hospital Stay Needs” (Chronic Pain Partners) – planning for surgery: <https://www.chronicpainpartners.com/wp-content/uploads/2023/02/surgery-prep-meeting-your-eds-hospital-stay-needs.pdf>
- Surgical prep guide for patients: <https://hypermobilityclinic.org/surgical-and-anesthetic-precautions-for-hypermobility-and-eds-patients/>
- Leslie’s surgical precautions handout (more for providers than patients): <https://webpace.clarkson.edu/~lrussek/docs/hypermobility/SurgeryHSD.pdf>
- Dental surgery guide to EDS: <https://www.rareconnect.org/uploads/documents/eds-dentistry-medical-resource-guide.pdf>
- Web site with info to share with your doctors: <https://hypermobilityclinic.org/surgical-and-anesthetic-precautions-for-hypermobility-and-eds-patients/>



Surgical and Anesthetic Precautions:
Hypermobility Spectrum Disorder (HSD) and
Hypermobile Ehlers Danlos Syndrome (hEDS)

The main feature of HSD/hEDS is *laxity of connective tissue*, including skin, ligaments, blood vessels and nerves. This can cause *potentially fatal problems* for these patients when unconscious, and/or having surgery.

BEWARE THE UNCONSCIOUS PATIENT!	<i>In the unconscious HSD/hEDS patient, a little force may displace any joint.</i> Treat unconscious HSD/hEDS patients with full spinal stabilization as if they have a spinal injury. If you don't, then you may cause one! <i>Use NO traction on limbs.</i> <i>Use extreme care with the chest:</i> the ribs easily dislocate front or back.
BEWARE THE LARYNGOSCOPE!	<i>Use extreme gentleness, with minimal, if any, anterior traction on the laryngoscope. The jaw may dislocate</i> on one or both sides. Manipulation of the laryngoscope can also damage the cricopharyngeal muscle and its nerves, the esophagus and the cervical spine.
BEWARE NECK MOTION!	<i>Keep patient's head in neutral position throughout.</i> Movement of unstable subcranial joints may cause spinal cord damage during incautious patient handling during anesthesia. Consider a soft collar.
LOCAL ANESTHESIA	HSD/hEDS patients are often resistant to local anesthetics: they may need much larger doses than other patients, and these may need to be repeated during a procedure. Ropivacaine may work better than lidocaine or bupivacaine.
SURGICAL TECHNIQUE	Use minimal force when cutting or moving tissues. Cut blood vessels may contract poorly: electrocautery is appropriate. Tissue healing may be prolonged. Close layers without tension using slowly-absorbable or non-absorbable sutures. Reinforce them with steri-strips etc. as appropriate.
BLEEDING & BRUISING	These are due to fragile small blood vessels, not an intrinsic blood disorder, so elaborate clotting tests are rarely indicated. Be alert for slowly-accumulating, deep hematomas.
POST-OPERATIVE PAIN	Painful polyneuropathy is common in HSD/hEDS. Post-operative pain may be more severe and more prolonged than normal. Be liberal with analgesics.
CARDIO-VASCULAR INSTABILITY	HSD/hEDS patients are subject to hypotension and/or tachycardia due to low blood volume, and defective venoconstriction. Liberal IV fluids usually can address this.
GI DYSFUNCTION	Poor GI motility is routine in HSD/hEDS, worse after surgery. Minimize constipating agents, and use laxatives pre-emptively. Consider pro-motility agents.
CARDIAC RESCUCITATION	Some HSD/hEDS patients have loose costosternal joints , sometimes palpably displaced. For them, chest compressions could in theory be very dangerous, causing rib detachments, a flail chest and even heart or lung puncture by freed anterior ribs. There is no consensus on whether cardiac resuscitation should include chest compressions in patients with clear evidence of rib displacements.

Alan Spanos, MD, (919) 967-2927, alan.spanos@yahoo.com.


This document is online at www.AlanSpanosMD.com. It was updated March 2019.

For more information, see the Ehlers Danlos Society at ehlers-danlos.com.

Handout for patients to share with surgeons and anesthesiologists

This handout and many others to share with your health care providers by Dr. Spanos, MD (retired)
<https://rachelleepac.com/spanos-resources/>


Also included in my Surgical Precautions handout



Wallet Information Card!

<p>I have.. Hypermobile Ehlers-Danlos Syndrome (hEDS)</p>	
 The Ehlers-Danlos Society	www.ehlers-danlos.com/hEDS/

This emergency card (and others), can be accessed on the Ehlers-Danlos Society website: <https://www.ehlers-danlos.com/download-your-wallet-card/>




MD Resources For HSD/hEDS

- Wiesmann T, Castori M, Malfait F, Wulf H. Recommendations for anesthesia and perioperative management in patients with Ehlers-Danlos syndrome(s). *Orphanet J Rare Dis*. 2014 Jul 23;9:109. doi: 10.1186/s13023-014-0109-5. PMID: 25053156; PMCID: PMC4223622. Has table of risks and surgical flow chart: <https://www.ncbi.nlm.nih.gov/pmc/articles/PMC4223622/>
- Laserna A, Nishtar M, Vidovich C, Borovcanin Z. Perioperative Management of Ehlers-Danlos Type III Syndrome Associated With Postural Orthostatic Tachycardia in Patients Undergoing General Anesthesia. *Cureus*. 2021 Nov 6;13(11):e19311. doi: 10.7759/cureus.19311. <https://pmc.ncbi.nlm.nih.gov/articles/PMC8575340/>
- Clarke JE, Santana J, Manjarrez EC. Hospital Stay Considerations in Hypermobile Ehlers-Danlos Syndrome: An Exemplary Case With Insights for Coexisting Symptoms. *AIM Clinical Cases*. 2022;2022;1:e220154. [Epub 21 June 2022]. doi:10.7326/aimcc.2022.0154. <https://www.acpjournals.org/doi/full/10.7326/aimcc.2022.0154>
- Chopra P, Bluestein L. Perioperative Care in Patients with Ehlers Danlos Syndromes. *Open Journal of Anesthesiology*. 2020;10:13-2913. doi:10.4236/ojanes.2020.101002. Reproduced according to open access license. Available at https://www.scirp.org/pdf/ojanes_2019123013435518.pdf .

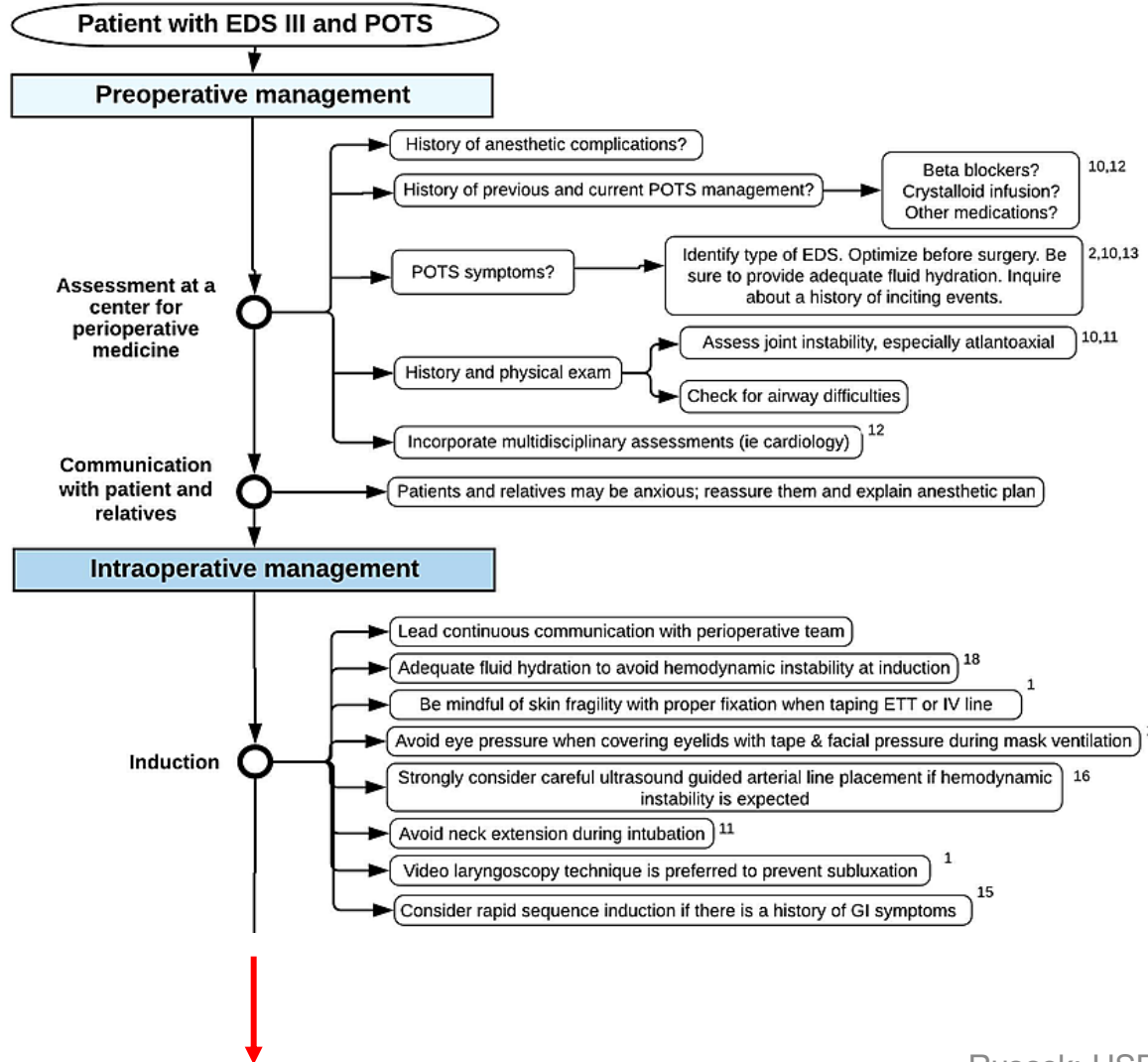
Surgical Concerns

Table 1. Considerations for dealing with patients with EDS.

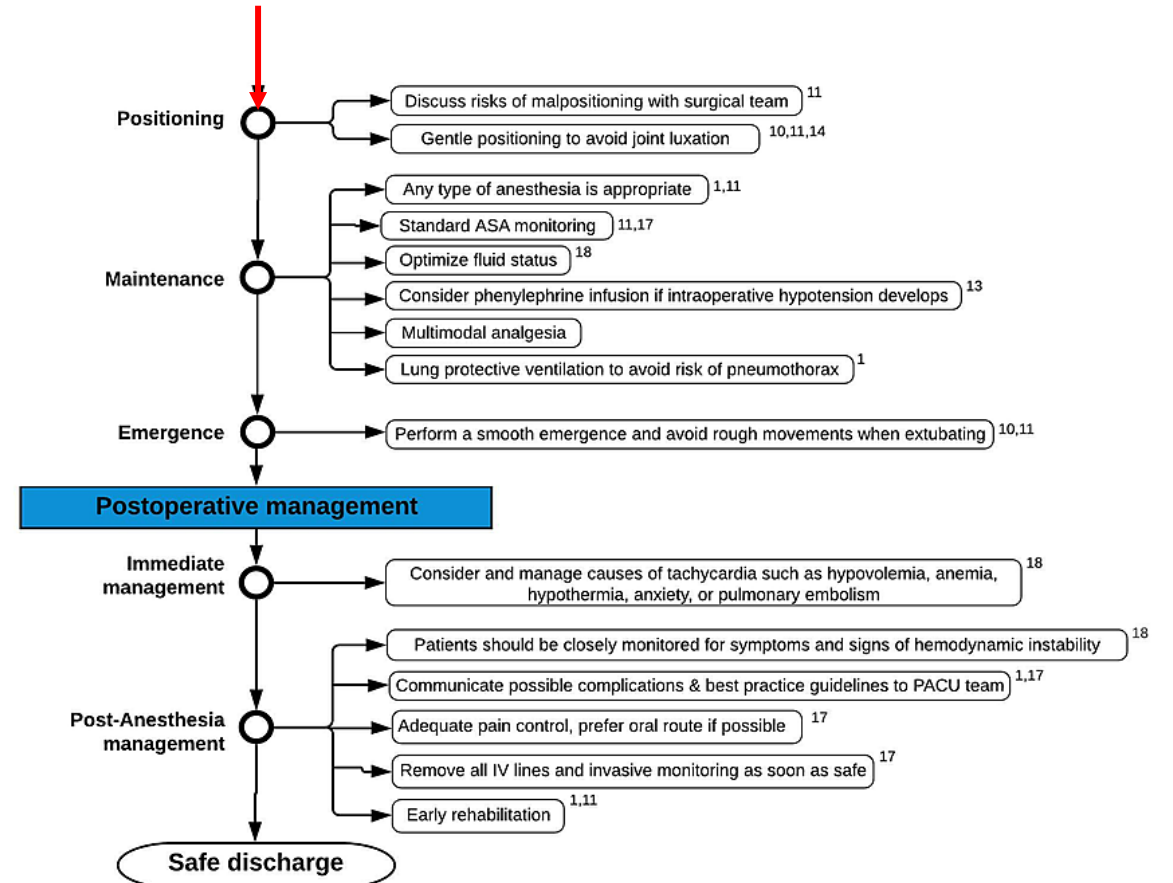
Head and neck (6) Chiari malformation Brain stem compression Idiopathic intracranial hypertension Atlantoaxial instability Cranio cervical instability Epilepsy Intracranial aneurysm Temporomandibular joint dysfunction (7) Headaches and migraines (8) Intermittent compression of vertebral arteries Compression of upper cervical nerve roots from C0 to C2 hypermobility (6))	GI (19) Gastroparesis Intestinal dysmotility (14) Visceroptosis (15) Hollow visceral (intestines, uterus) rupture Rectal/uterine prolapse (16) Visceral fragility (dEDS and vEDS)
Spine (6) Segmental kyphosis and instability Tethered cord syndrome Tarlov cyst syndrome (8) Meningeal ecstasias/cysts Spontaneous cerebrospinal leak (9)	Urinary Neurogenic bladder (6, 17) Interstitial cystitis (20)
Cardiovascular Structural defects such as mitral valve prolapse and aortic root dilatation (hEDS) (11, 17, 18) Dysautonomia (10) Increased peripheral pooling (12) Severe progressive cardiac-valvular aortic valve and mitral valve problems (cvEDS)	Musculoskeletal (8) Joint subluxations and dislocations (8) Myopathy (25) Fatigue (22) Poor joint proprioception (23) Muscle weakness, axonal polyneuropathy, atrophy of muscles of hands and feet (24)
Pulmonary Tracheomalacia Rib subluxations Pulmonary bullae Decreased pulmonary volumes secondary to kyphoscoliosis Obstructive sleep apnea (13)	Hematologic Bleeding disorders (20) Mast cell activation syndrome (20, 21) Vascular fragility Neurological Dysautonomia (22) Postural orthostatic tachycardia syndrome (22,) Neuropathy (26, 27) Small fiber peripheral neuropathy (28) Entrapment neuropathy (24, 27, 28) Unpredictable response to local anesthetic
DOI: 10.4236/ojanes.2020.101002 15 Open Journal of Anesthesiology	



HSD & POTS Surgical Precautions



Laserna A, Nishtar M, Vidovich C, Borovcanin Z. 2021. Perioperative Management of Ehlers-Danlos Type III Syndrome Associated With Postural Orthostatic Tachycardia in Patients Undergoing General Anesthesia. *Cureus*. 13(11):e19311. 10.7759/cureus.19311 (used according to Creative Commons) (Citations in this diagram are numbered according to the article it appeared in, not according to this presentation)



Surgical Resources: POTS & MCAS

- Ruzieh M, Dziuba M, Hofmann JP, Grubb BP. Surgical and dental considerations in patients with postural tachycardia syndrome. *Auton Neurosci*. Dec 2018;215:119-120. doi:10.1016/j.autneu.2018.04.003
 - [https://www.autonomicneuroscience.com/article/S1566-0702\(18\)30032-8/fulltext](https://www.autonomicneuroscience.com/article/S1566-0702(18)30032-8/fulltext)
- Laserna A, Nishtar M, Vidovich C, Borovcanin Z. Perioperative Management of Ehlers-Danlos Type III Syndrome Associated With Postural Orthostatic Tachycardia in Patients Undergoing General Anesthesia. *Cureus*. 2021 Nov 6;13(11):e19311. doi: 10.7759/cureus.19311.
 - <https://pmc.ncbi.nlm.nih.gov/articles/PMC8575340/>
- Perioperative Management for Patients with Mast Cell Diseases
 - <https://tmsforcure.org/perioperative-management/>



References (might not be complete)

1. Safwat S, Safwat F, Sivanathan N, Daka N, Sadek M. Misdiagnosed Seizure-Like Activity in a Patient With Postural Orthostatic Tachycardia Syndrome: A Case Report. *Cureus*. May 2023;15(5):e39565. doi:10.7759/cureus.39565
2. Vernino S, Bourne KM, Stiles LE, et al. Postural orthostatic tachycardia syndrome (POTS): State of the science and clinical care from a 2019 National Institutes of Health Expert Consensus Meeting - Part 1. *Auton Neurosci*. Nov 2021;235:102828. doi:10.1016/j.autneu.2021.102828
3. Russek LN, Block NP, Byrne E, et al. Presentation and physical therapy management of upper cervical instability in patients with symptomatic generalized joint hypermobility: International expert consensus recommendations. *Front Med (Lausanne)*. 2022;9:1072764. doi:10.3389/fmed.2022.1072764
4. Lohkamp LN, Marathe N, Fehlings MG. Craniocervical Instability in Ehlers-Danlos Syndrome-A Systematic Review of Diagnostic and Surgical Treatment Criteria. *Global Spine J*. Feb 23 2022:21925682211068520. doi:10.1177/21925682211068520
5. Fant C, Cohen A. Syncope In Pediatric Patients: A Practical Approach To Differential Diagnosis And Management In The Emergency Department. *Pediatr Emerg Med Pract*. Apr 2017;14(4):1-28.
6. Kesserwani H. Postural Orthostatic Tachycardia Syndrome Misdiagnosed as Anxiety: A Case Report with a Review of Therapy and Pathophysiology. *Cureus*. Oct 10 2020;12(10):e10881. doi:10.7759/cureus.10881
7. Weinstock LB, Nelson RM, Blitshteyn S. Neuropsychiatric Manifestations of Mast Cell Activation Syndrome and Response to Mast-Cell-Directed Treatment: A Case Series. *J Pers Med*. Oct 31 2023;13(11)doi:10.3390/jpm13111562
8. Russek LN, Stott P, Simmonds J. Recognizing and Effectively Managing Hypermobility-Related Conditions. *Phys Ther*. Sep 1 2019;99(9):1189-1200. doi:10.1093/ptj/pzz078
9. Nicholson LL, Simmonds J, Pacey V, et al. International Perspectives on Joint Hypermobility: A Synthesis of Current Science to Guide Clinical and Research Directions. *J Clin Rheumatol*. Sep 1 2022;28(6):314-320. doi:10.1097/RHU.0000000000001864
10. Simmonds JV. Masterclass: Hypermobility and hypermobility related disorders. *Musculoskelet Sci Pract*. Feb 2022;57:102465. doi:10.1016/j.msksp.2021.102465
11. Daylor V, Gensemer C, Norris RA, Bluestein L. Hope for Hypermobility: Part 1—An Integrative Approach to Treating Symptomatic Joint Hypermobility. *Topics in Pain Management*. 2023;38(8):1-9. doi:10.1097/01.TPM.0000924780.91929.b3
12. Afrin LB, Self S, Menk J, Lazarchick J. Characterization of Mast Cell Activation Syndrome. *Am J Med Sci*. Mar 2017;353(3):207-215. doi:10.1016/j.amjms.2016.12.013
13. Henderson FC, Sr., Austin C, Benzel E, et al. Neurological and spinal manifestations of the Ehlers-Danlos syndromes. *Am J Med Genet C Semin Med Genet*. Mar 2017;175(1):195-211. doi:10.1002/ajmg.c.31549

References

15. Raj SR, Guzman JC, Harvey P, et al. Canadian Cardiovascular Society Position Statement on Postural Orthostatic Tachycardia Syndrome (POTS) and Related Disorders of Chronic Orthostatic Intolerance. *Can J Cardiol*. Mar 2020;36(3):357-372. doi:10.1016/j.cjca.2019.12.024
16. Rugg-Gunn FJ. Rugg-Gunn, FJ. Non-epileptic paroxysmal neurological and cardiac events: the differential diagnosis of epilepsy. 2009;
17. Bagcier F, Yurdakul O, Ozduran E. Three Simple Rules in Pectoral Muscle's Trigger Point Treatment, Which May Be a Cause of Chest Pain: Position, Palpation, and Perpendicular Needling. *J Am Board Fam Med*. Nov-Dec 2020;33(6):1031. doi:10.3122/jabfm.2020.06.200342
18. Tocchioni F, Ghionzoli M, Messineo A, Romagnoli P. Pectus excavatum and heritable disorders of the connective tissue. *Pediatr Rep*. Sep 24 2013;5(3):e15. doi:10.4081/pr.2013.e15
19. Ritter A, Atzinger C, Hays B, et al. Natural history of aortic root dilation through young adulthood in a hypermobile Ehlers-Danlos syndrome cohort. *Am J Med Genet A*. Jun 2017;173(6):1467-1472. doi:10.1002/ajmg.a.38243
20. Kumskova M, Flora GD, Staber J, Lentz SR, Chauhan AK. Characterization of bleeding symptoms in Ehlers-Danlos syndrome. *J Thromb Haemost*. Jul 2023;21(7):1824-1830. doi:10.1016/j.jtha.2023.04.004
21. Wright TS, Cygan PH. Closing the Diagnostic Gap in Adolescents and Young Adult Women With Bleeding Disorders: Missed Opportunities. *Obstet Gynecol*. Aug 1 2023;142(2):251-256. doi:10.1097/aog.0000000000005262
22. Kendel NE, Stanek JR, Thomas BB, Ardoin SP, O'Brien SH. Assessing Bleeding Symptoms in Pediatric Patients With Generalized Joint Hypermobility. *Arthritis Care Res (Hoboken)*. Aug 2023;75(8):1788-1794. doi:10.1002/acr.25074
23. Schofield JR, Afrin LB. Recognition and Management of Medication Excipient Reactivity in Patients With Mast Cell Activation Syndrome. *Am J Med Sci*. Jun 2019;357(6):507-511. doi:10.1016/j.amjms.2019.03.005
24. Russek LN. Chronic Pain. In: O'Sullivan SB, Schmitz TJ, Fulk G, eds. *Physical Rehabilitation, 7e*. 2022 online edition ed. F. A. Davis Company; 2022.
25. Wig R, Oakley CB. Dysautonomia and Headache in the Pediatric Population. *Headache*. Oct 2019;59(9):1582-1588. doi:10.1111/head.13659
26. Johansson M, Ståhlberg M, Runold M, et al. Long-Haul Post-COVID-19 Symptoms Presenting as a Variant of Postural Orthostatic Tachycardia Syndrome: The Swedish Experience. *JACC Case Rep*. Mar 10 2021;doi:10.1016/j.jaccas.2021.01.009
27. Conti P, D'Ovidio C, Conti C, et al. Progression in migraine: Role of mast cells and pro-inflammatory and anti-inflammatory cytokines. *Eur J Pharmacol*. Feb 5 2019;844:87-94. doi:10.1016/j.ejphar.2018.12.004
28. Wang C, Wang H, Lei H. Increased Risks of Botulinum Toxin Injection in Patients with Hypermobility Ehlers Danlos Syndrome: A Case Series. *Mov Disord*. 2018;33(suppl 2)
29. Bennett K, Diamond C, Hoeritzauer I, et al. A practical review of functional neurological disorder (FND) for the general physician. *Clin Med (Lond)*. Jan 2021;21(1):28-36. doi:10.7861/clinmed.2020-0987

References

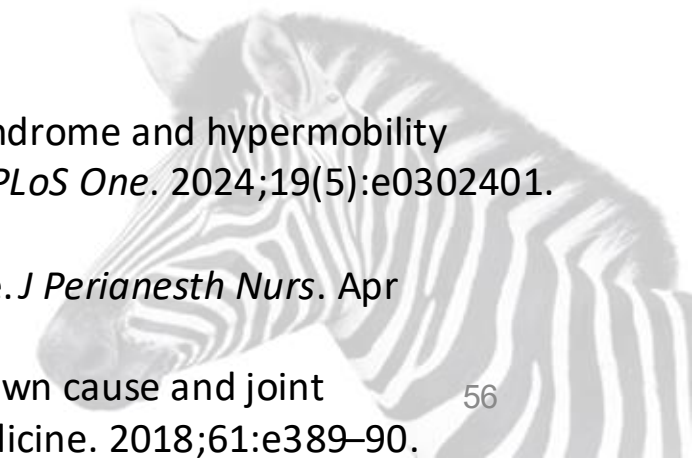
30. DiBaise JK, Harris LA, Goodman B. Postural Tachycardia Syndrome (POTS) and the GI Tract: A Primer for the Gastroenterologist. *Am J Gastroenterol*. Oct 2018;113(10):1458-1467. doi:10.1038/s41395-018-0215-4
31. Weinstock LB, Pace LA, Rezaie A, Afrin LB, Molderings GJ. Mast Cell Activation Syndrome: A Primer for the Gastroenterologist. *Dig Dis Sci*. Apr 2021;66(4):965-982. doi:10.1007/s10620-020-06264-9
32. Lam C, Amarasinghe G, Zarate-Lopez N, et al. Gastrointestinal symptoms and nutritional issues in patients with hypermobility disorders: assessment, diagnosis and management. *Frontline Gastroenterol*. 2023;14(1):68-77. doi:10.1136/flgastro-2022-102088
33. Huynh DTK, Shamash K, Burch M, et al. Median Arcuate Ligament Syndrome and Its Associated Conditions. *Am Surg*. Oct 1 2019;85(10):1162-1165.
34. Sandmann W, Scholbach T, Verginis K. Surgical treatment of abdominal compression syndromes: The significance of hypermobility-related disorders. *Am J Med Genet C Semin Med Genet*. Dec 2021;187(4):570-578. doi:10.1002/ajmg.c.31949
35. Castori M. Surgical recommendations in Ehlers-Danlos syndrome(s) need patient classification: the example of Ehlers-Danlos syndrome hypermobility type (a.k.a. joint hypermobility syndrome). *Dig Surg*. 2012;29(6):453-5. doi:10.1159/000346068
36. Doolan BJ, Lavalley M, Hausser I, et al. Dermatologic manifestations and diagnostic assessments of the Ehlers-Danlos syndromes: A clinical review. *J Am Acad Dermatol*. Sep 2023;89(3):551-559. doi:10.1016/j.jaad.2023.01.034
37. Mihele DM, Nistor PA, Bruma G, et al. Mast Cell Activation Syndrome Update-A Dermatological Perspective. *J Pers Med*. Jul 10 2023;13(7)doi:10.3390/jpm13071116
38. Gilliam E, Hoffman JD, Yeh G. Urogenital and pelvic complications in the Ehlers-Danlos syndromes and associated hypermobility spectrum disorders: A scoping review. *Clin Genet*. Jan 2020;97(1):168-178. doi:10.1111/cge.13624
39. Bascom R, Dhingra R, Francomano CA. Respiratory manifestations in the Ehlers-Danlos syndromes. *Am J Med Genet C Semin Med Genet*. Dec 2021;187(4):533-548. doi:10.1002/ajmg.c.31953
40. Dorff SR, Afrin LB. Mast cell activation syndrome in pregnancy, delivery, postpartum and lactation: a narrative review. *J Obstet Gynaecol*. Oct 2020;40(7):889-901. doi:10.1080/01443615.2019.1674259
41. Rombaut L, Malfait F, De Wandele I, et al. Medication, surgery, and physiotherapy among patients with the hypermobility type of Ehlers-Danlos syndrome. *Arch Phys Med Rehabil*. Jul 2011;92(7):1106-12. doi:10.1016/j.apmr.2011.01.016
42. Yonko EA, LoTurco HM, Carter EM, Raggio CL. Orthopedic considerations and surgical outcomes in Ehlers-Danlos syndromes. *Am J Med Genet C Semin Med Genet*. Dec 2021;187(4):458-465. doi:10.1002/ajmg.c.31958
43. Homere A, Bolia IK, Juhan T, Weber AE, Hatch GF. Surgical Management of Shoulder and Knee Instability in Patients with Ehlers-Danlos Syndrome: Joint Hypermobility Syndrome. *Clin Orthop Surg*. Sep 2020;12(3):279-285. doi:10.4055/cios20103
44. Laserna A, Nishtar M, Vidovich C, Borovcanin Z. Perioperative Management of Ehlers-Danlos Type III Syndrome Associated With Postural Orthostatic Tachycardia in Patients Undergoing General Anesthesia. *Cureus*. Nov 2021;13(11):e19311. doi:10.7759/cureus.19311

References


45. Chi J, Raso J, Tadepalli V, et al. Outcomes Following Anterior Cervical Discectomy and Fusion in Patients With Ehlers-Danlos Syndrome. *Global Spine J*. Jan 16 2023;21925682231151924. doi:10.1177/21925682231151924
46. Kulas Sjøborg ML, Leganger J, Rosenberg J, Burcharth J. Increased Need for Gastrointestinal Surgery and Increased Risk of Surgery-Related Complications in Patients with Ehlers-Danlos Syndrome: A Systematic Review. *Dig Surg*. 2017;34(2):161-170. doi:10.1159/000449106
47. Burcharth J, Rosenberg J. Gastrointestinal surgery and related complications in patients with Ehlers-Danlos syndrome: a systematic review. *Dig Surg*. 2012;29(4):349-57. doi:10.1159/000343738
48. Ericson WB, Jr., Wolman R. Orthopaedic management of the Ehlers-Danlos syndromes. *Am J Med Genet C Semin Med Genet*. Mar 2017;175(1):188-194. doi:10.1002/ajmg.c.31551
49. Ruzieh M, Dziuba M, Hofmann JP, Grubb BP. Surgical and dental considerations in patients with postural tachycardia syndrome. *Auton Neurosci*. Dec 2018;215:119-120. doi:10.1016/j.autneu.2018.04.003
50. Chopra P, Bluestein L. Perioperative Care in Patients with Ehlers Danlos Syndromes. *Open Journal of Anesthesiology*. 2020;10:13-2913. doi:10.4236/ojanes.2020.101002.

New references

- Pezaro S, Brock I, Buckley M, et al. Management of childbearing with hypermobile Ehlers-Danlos syndrome and hypermobility spectrum disorders: A scoping review and expert co-creation of evidence-based clinical guidelines. *PLoS One*. 2024;19(5):e0302401. doi:10.1371/journal.pone.0302401
- Hubbard JA, Wolfe RC. Perioperative Considerations in Patients With Mast Cell Activation Syndrome. *J Perianesth Nurs*. Apr 2023;38(2):357-360. doi:10.1016/j.jopan.2023.01.008
- Sanchez-Raya J, Altisent C, Martorell M, Corrales., Vidal E, Crespo A. Patients with bleeding of unknown cause and joint hypermobility: Clinical assessment and genetic screening. *Annals of Physical and Rehabilitation Medicine*. 2018;61:e389–90.



Thank
You!





Questions?

