Hypermobility 111a: Cervical Instability Part 1

- Leslie Russek, PT, DPT, PhD, OCS
- Clarkson University,
- Canton-Potsdam Hospital,
- Potsdam, NY

- Slide handouts and recording available at: https://webspace.clarkson.edu/~lrussek/hsd.html

Clarkson UNIVERSITY

Who Am I?

- Professor Emeritus, Physical Therapy Dept, Clarkson University
- Staff PT, St. Lawrence Health System, Potsdam NY
  - Clinical specialties: hypermobility, fibromyalgia, headaches, temporomandibular disorders
- Frequent presenter to professional and patient groups at national conferences
- Author of multiple review and research articles on hypermobility
- Member of the Allied Health Working Group of the International Consortium of Ehlers-Danlos Syndromes and Hypermobility Spectrum Disorders
- National Academy of Science and Engineering Committee on Selected Heritable Connective Tissue Disorders and Disability
- Lrussek@Clarkson.edu
- https://webspace.clarkson.edu/~lrussek/

I do not have any conflicts of interest to report

Hypermobility Lecture Series

I will refer to these if you want more info

- HSD 101: Basics of HSD/hEDS and self-care
- 9/24/21 - HSD 102: POTS and POTS self-care, basics of MCAS
- HSD 103: Pain management in HSD/hEDS
- HSD 104: Safe exercise selection and progression with HSD/hEDS
- **HSD 105: NEW: Posture and joint protection**
- HSD 106: Gut issues in HSD/hEDS, POTS, MCAS
- HSD 107: Fatigue in HSD/hEDS and POTS
- HSD 108: Headaches, migraines, and TMJ pain in HSD, POTS and MCAS
- HSD 109: Breathing dysfunctions in HSD
- HSD 110: Lumbar instability
- **HSD 110: Cervical instability (NEW)**

DISCLAIMER

The information in this presentation is for general purposes, only, and may or may not apply to your situation.
Check with your health care provider before starting any new exercises or treatments, to ensure that they are appropriate and safe for YOU.

NOTE: I have tried to collect reliable information, but I am not responsible if there are errors in this presentation.
This information can NOT be used to diagnose you, but it can provide a language with which to talk to your health care team.
Talk to your health care team to figure out what aspects of this lecture are most relevant to YOU!

Objectives

At the end of these 2 presentations, participants will be able to:

Part 1:

1. Identify key anatomical structures in the neck
2. List causes of cervical instability pain
3. Recognize signs and symptoms of cervical instability

Part 2

1. Identify things you can do to minimize cervical instability
2. Recognize when you CAN manage cervical instability, and when you need to see a neurosurgeon

HSD/hEDS Treatment Progression

Assist patient in managing systemic comorbidities: education, treatment and/or referral

HSD102: POTS & MCAS;
HSD106: GI issues;
HSD107: Fatigue

Decrease central and peripheral pain sensitization

HSD103: Pain Management
HSD109: Breathing

Educate for correct posture and joint alignment, body mechanics, joint protection, appropriate use of splints and braces

HSD105: Joint Protection

Proprioceptive and motor control training, with training to relax muscles that are guarding

Stabilization, strengthening, muscle flexibility, aerobic conditioning

HSD104: Exercise
HSD110: Lumbar Instability

Integration of proper alignment & movement into function

HSD105: Joint Protection

Education about flare management

HSD103: Pain Management
HSD109: Breathing

Anatomy

Cervical Anatomy

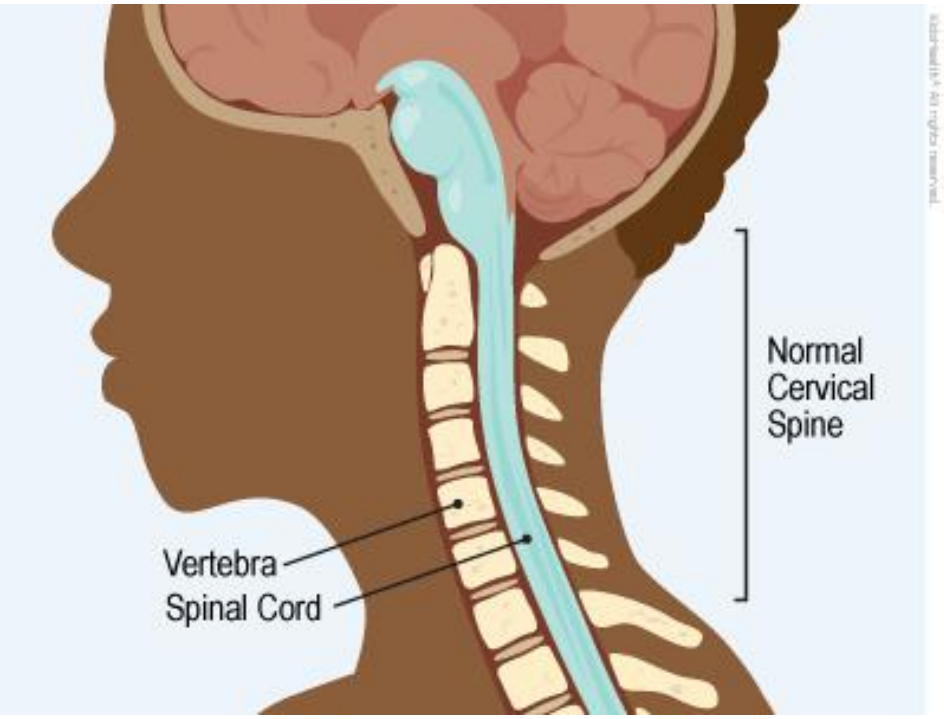

- The spinal cord travels through a tunnel behind vertebral bodies and discs (the supporting structures)
- The spinal cord connects to the brain stem, which connects to the brain
- The 'upper c-spine' refers to the skull and top two vertebrae, the atlas and axis
- Below that is the 'lower c-spine'

Organization of the Nervous System

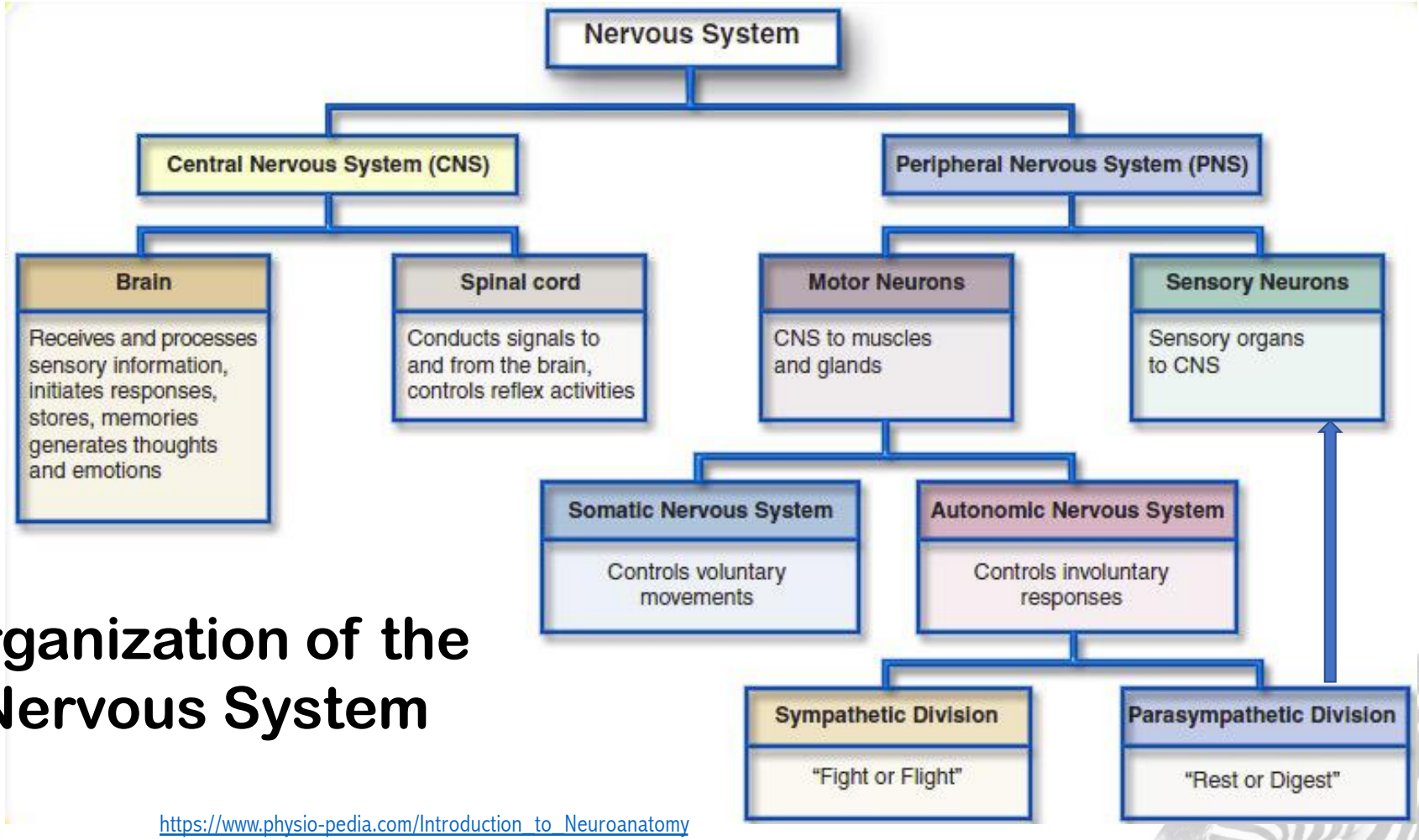

https://www.physio-pedia.com/Introduction_to_Neuroanatomy

Spine Anatomy

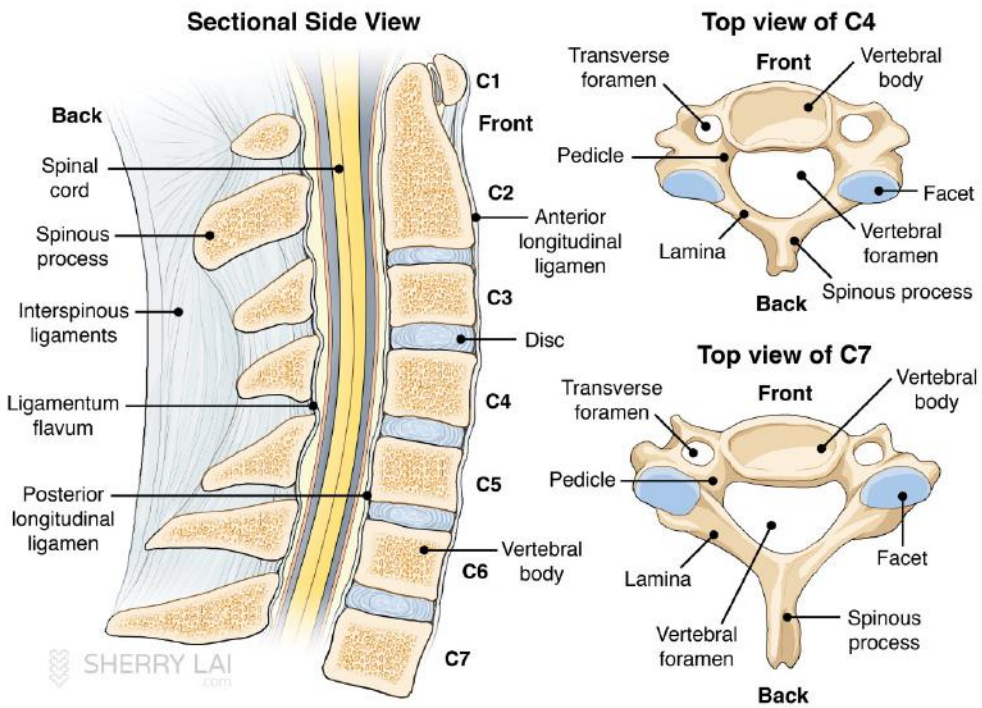

- The occiput, on the skull, connects to C1
- Craniocervical joint also called AO, atlanto-occipital joint (CCI is here)
- C1 also called the atlas
- C2 also called the axis (it serves as a hinge for C1)
- C1-C2 joint also called AA (CCI is here)
- Vertebrae are separated by intervertebral discs
  - Discs allow movement between vertebrae
- Vertebrae connect at facet joints
- Ligaments limit vertebral motion
- Muscles control vertebral motion

Atlas (C1) & Axis (C2) Are Unusual

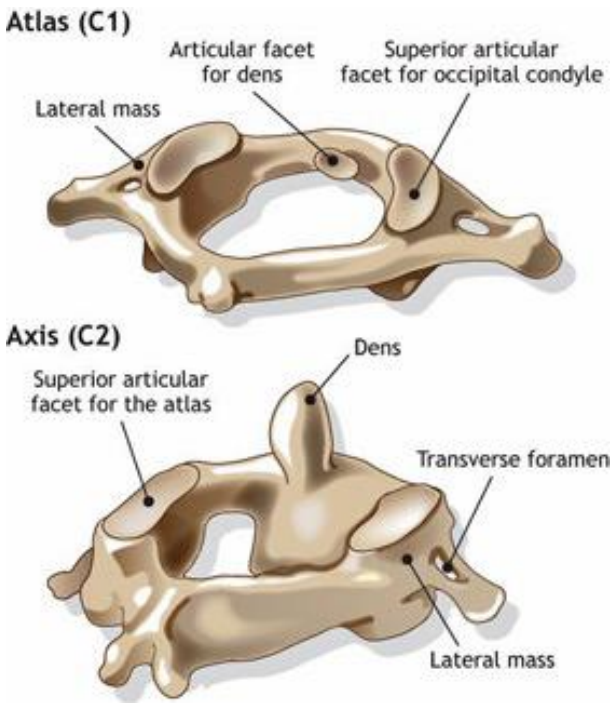

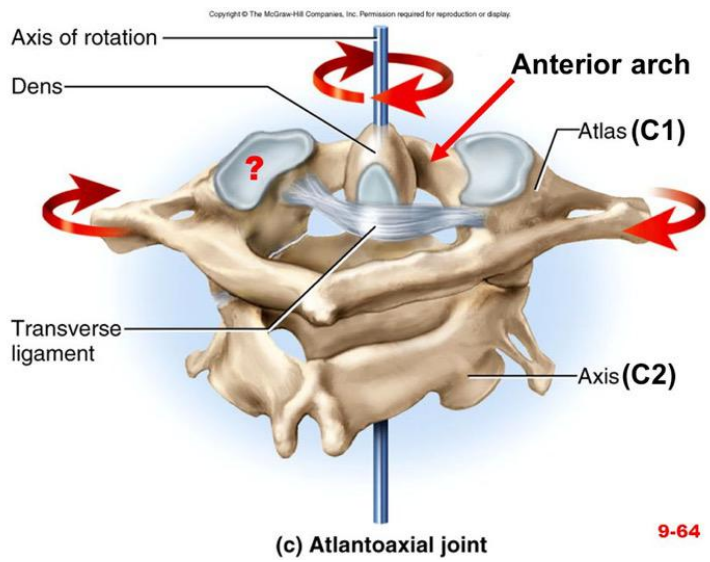

Total Spine Mobility

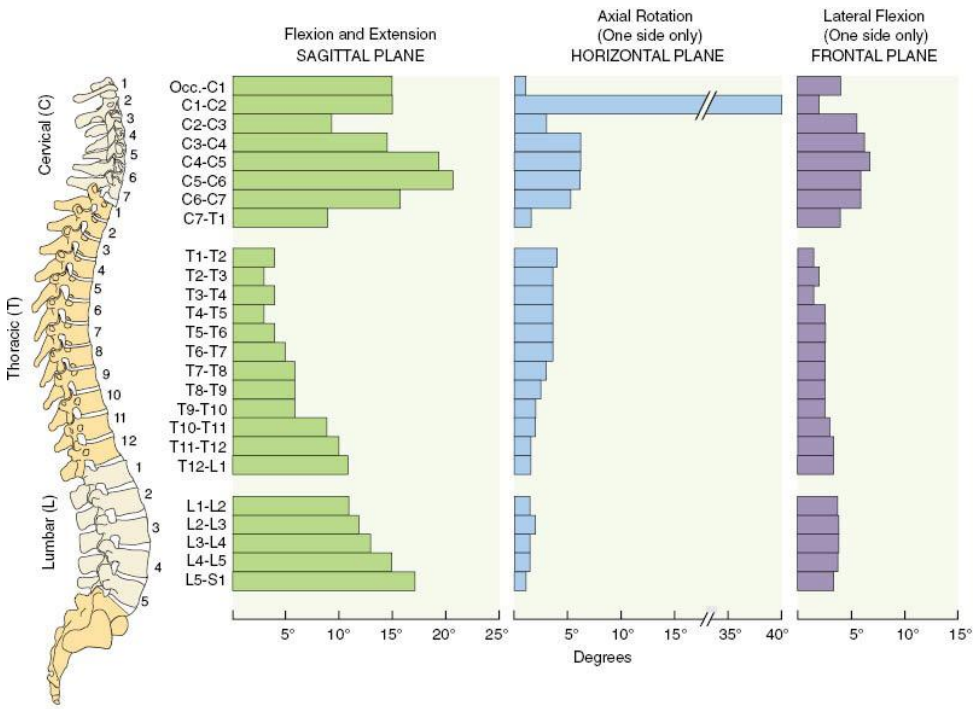

(Styled after White AA, Panjabi MM: Kinematics of the spine. In White AA, Panjabi MM, eds: *Clinical biomechanics of the spine*, Philadelphia, 1990, Lippincott.)

- Flexion/extension (front/back) is greatest in the neck
- Most rotation (axial rotation) in the neck occurs at the AA (C1-C2) joint
- Normally, the OA (skull-C1) does not move much

Atlantoaxial Instability

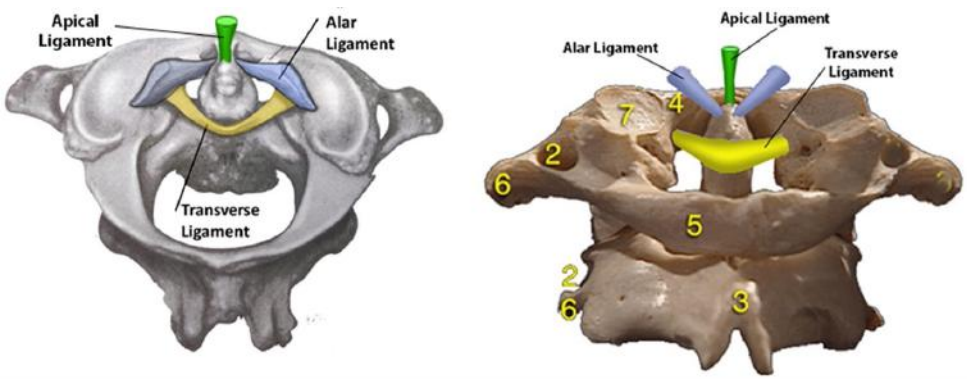

https://www.orthobullets.com/spine/2050/atlantoaxial-rotatory-displacement-aard

- About half of all neck rotation occurs at the AA joint (C1-C2)
- Rotational instability at the AA joint is common in HSD, due to laxity of the alar ligament
- C1 may also slip forward on C2: anterior instability, due to laxity of the transverse ligament
- Either can compress the spinal cord or stretch/compress cranial nerves

Neck Muscles

Sternocleidomastoid = SCM

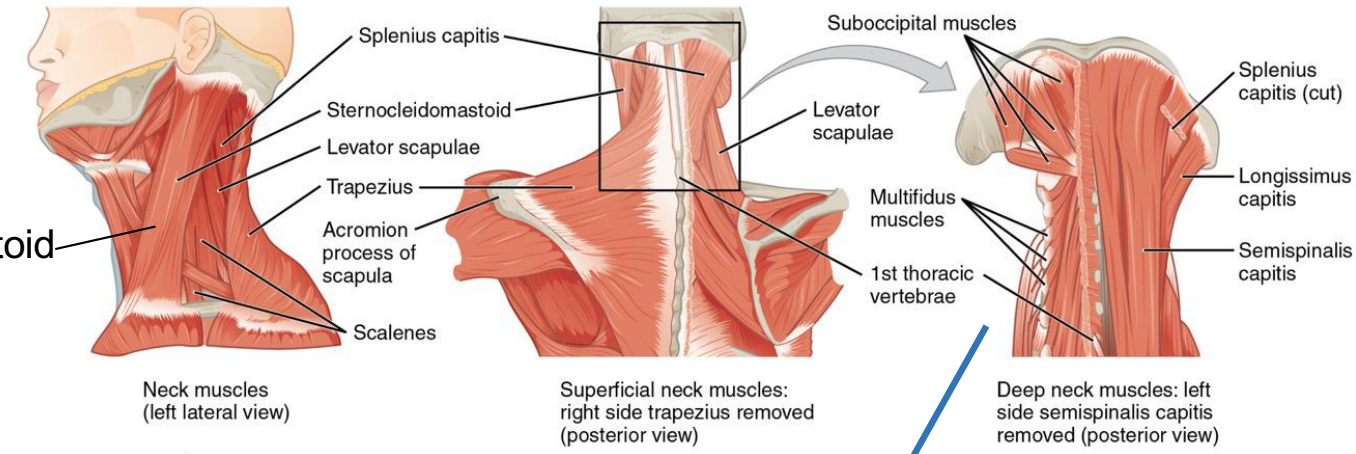

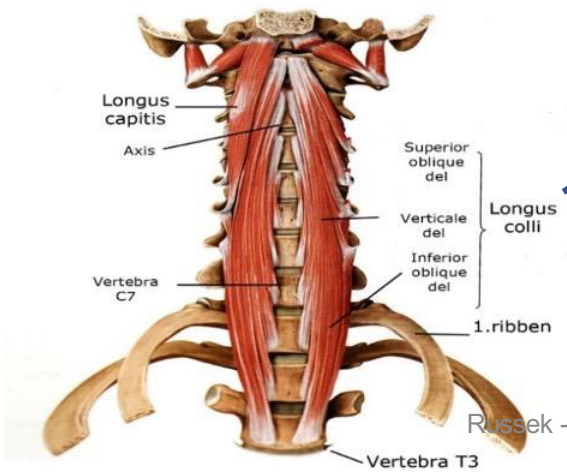

Deep neck muscles provide most stability:
Back: multifidi (lower) and suboccipitals (upper)
Front: “deep neck flexors (DNF)” or longus coli

Core Stabilization Concept

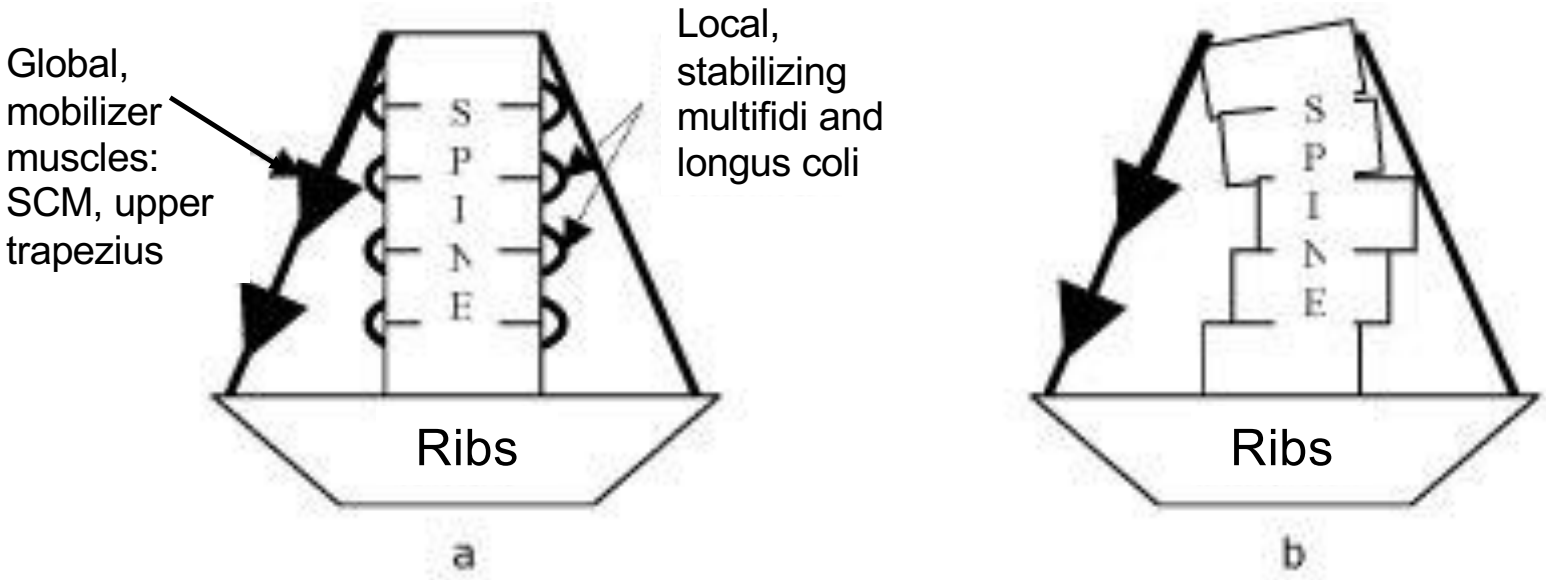

- Instability occurs when the short, deep, stabilizing muscles are not effective
- The long, superficial muscles try to help, but make instability worse
  - And cause pain by going into spasm

(picture from https://www.physio-pedia.com/images/d/dd/Ms_systems.jpg)

Body Awareness Role of Deep Muscles

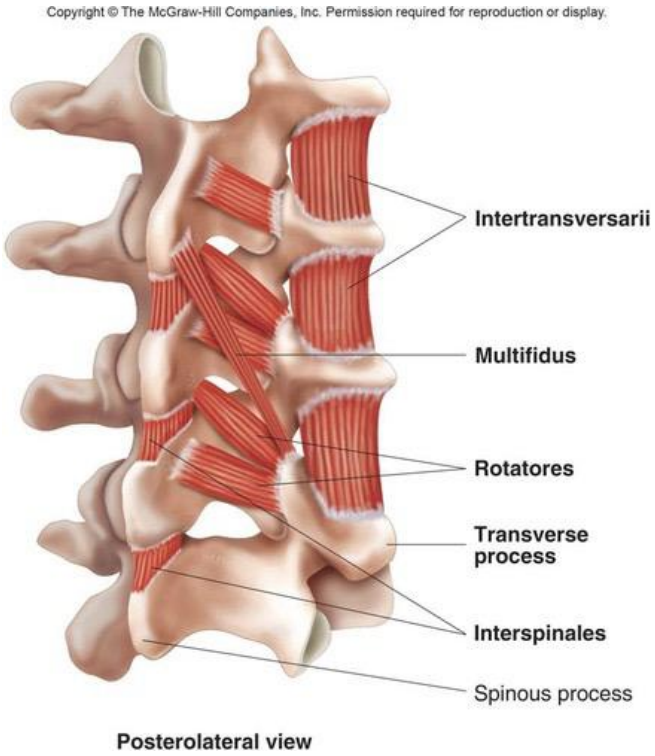

- Deep stabilizing muscles provide position and movement awareness in the spine
  - Deep muscles have more position sensing nerves than other muscles
- People with HSD/hEDS often have poor body awareness
- Treatment often needs to start with restoring this body awareness
  - Russo, 2018

https://brentbrookbush.com/articles/anatomy-articles/muscular-anatomy/rotatores-interspinales-and-intertransversarii/

When Muscles Don't Work Right…

- Local stabilizer dysfunction
  - (e.g., multifidi, deep neck flexors)
  - Are inhibited by pain
  - → poor segmental control & instability
- Global stabilizer
  - (e.g., semispinalis)
  - Difficulty controlling movement
  - Often become weak and long
- Global mobilizer
  - (e.g., sternocleidomastoid, upper trapezius, splenius)
  - Responds to pain by going into spasm
  - Tightness in these muscles causes imbalances elsewhere

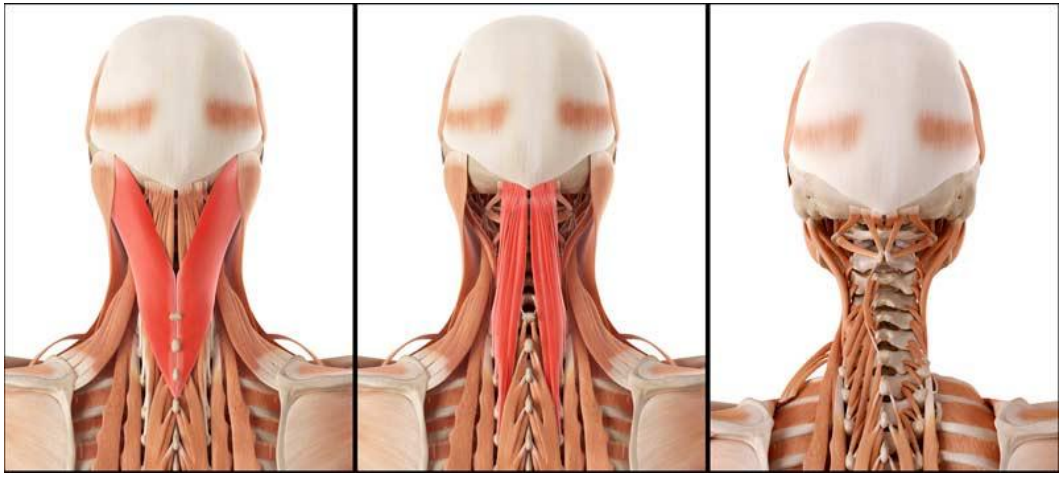

global mobilizer global stabilizer local stabilizers

(Gibbons, 2001)

Cranial Nerves

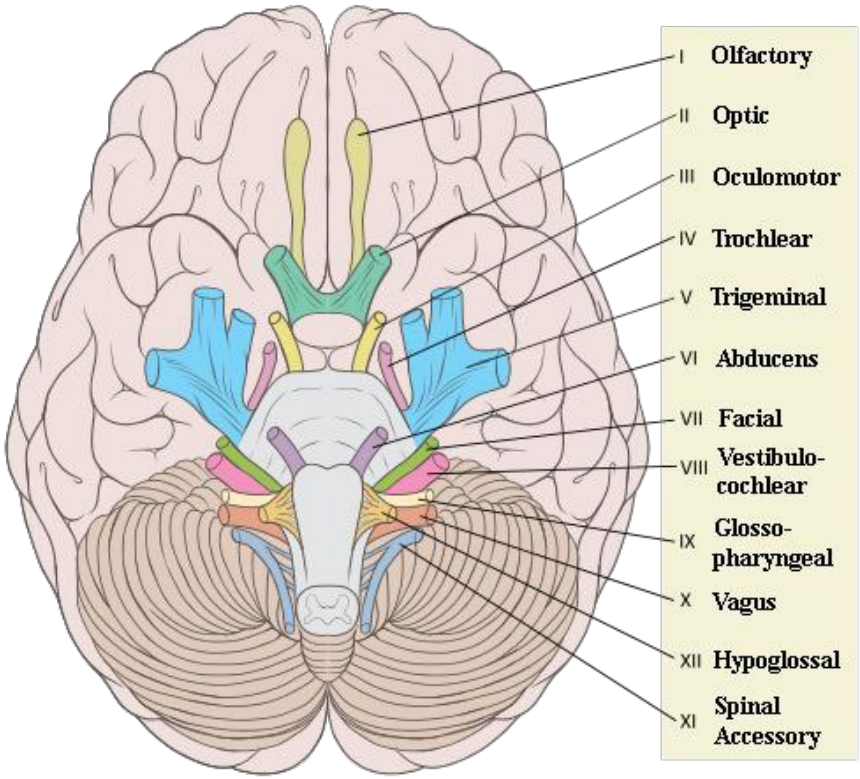

View from the bottom
https://www.vestib.com/CN-anatomy.html

- Cranial nerves)CN) come directly from the brain (not the spinal cord)
- Upper cervical instability can compress or stretch them
- CN III, VII, IX, X are most commonly affected

Brainstem

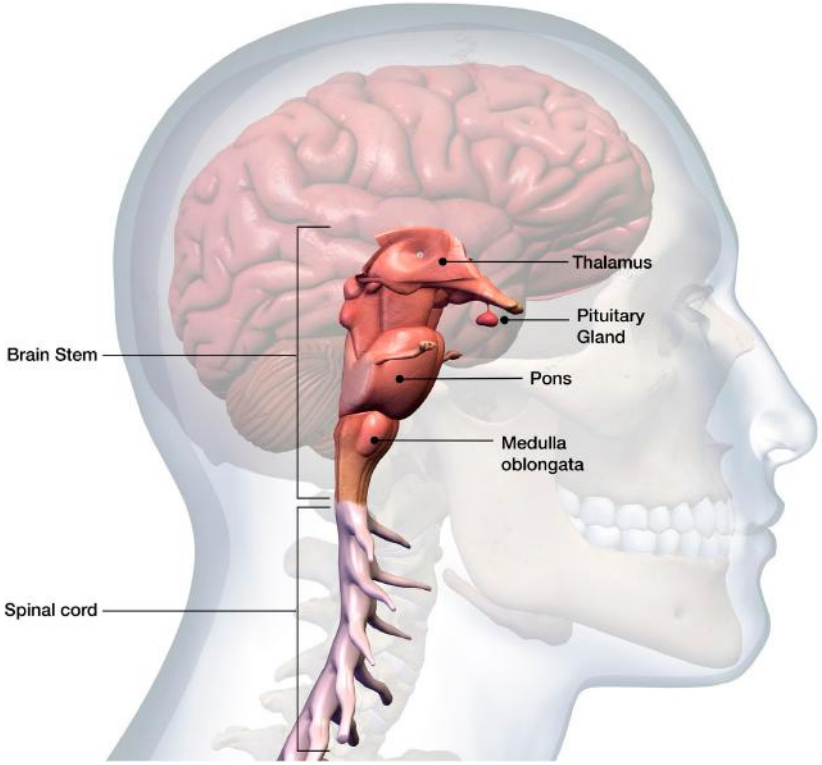

- The brainstem connect the spinal cord to the brain
- The lower part (medulla) may be compressed in upper cervical instability
- This may cause 'cervico-medullary syndrome'

Blood Flow To/From the Brain

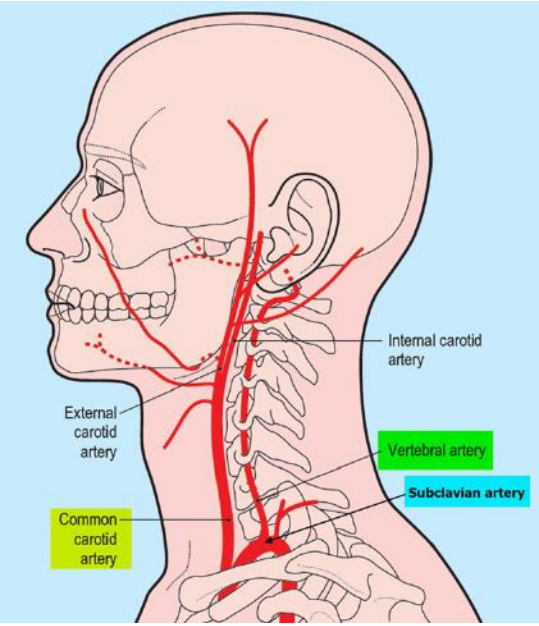

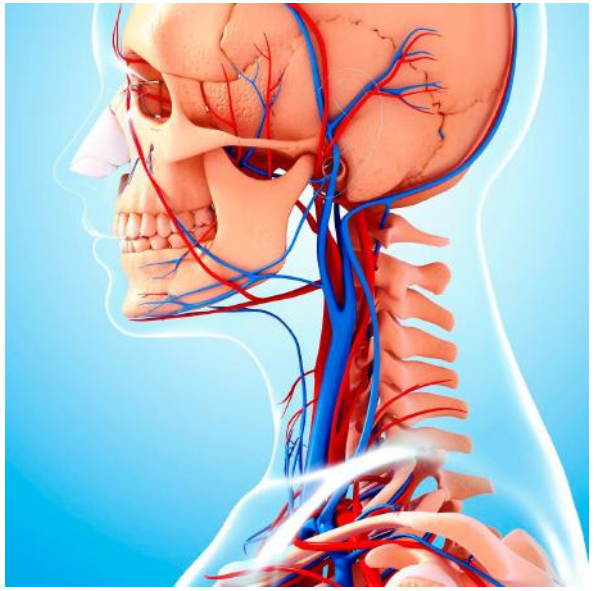

Internal jugular travels with carotid artery and vagus nerve

- Some problems associated with cervical instability may be due to compromised blood flow to, or drainage from the brain.
- Vertebral artery at risk primarily with cervical rotation
- Carotid artery at risk primarily with cervical extension
- There may also be problems with drainage from the brain via the internal jugular vein

- https://healthjade.com/vertebral-artery/

Vertebral Artery

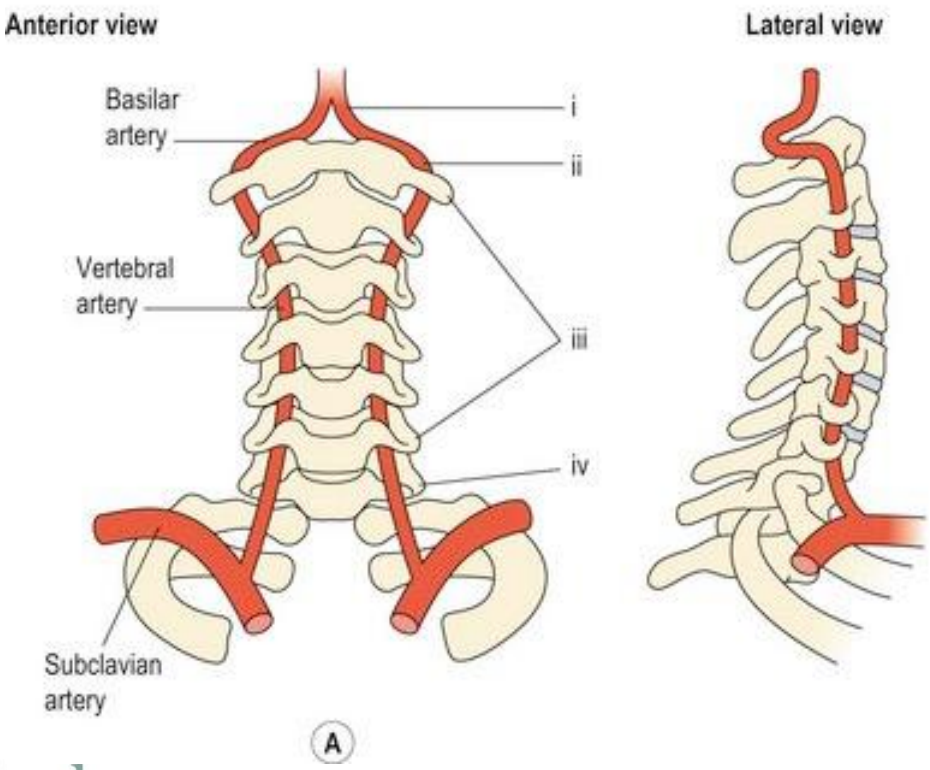

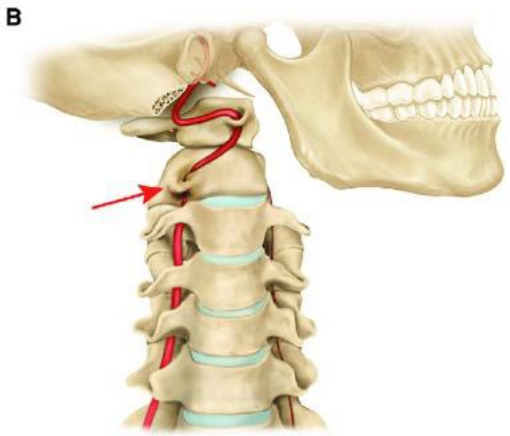

- The vertebral artery travels inside the ‘wings’ (transverse processes) of vertebrae in the neck
- Neck rotation pulls on the vertebral artery (shown above), and can compromise blood flow

https://www.researchgate.net/publication/236930499_Rotational_Vertebral_Artery_Occlusion_Mechanisms_and_Long-term_Outcome/figures?lo=1

Laxity and Systemic Issues

Not yet proven

- Mast cell activation (MCAD) may correlate with cervical instability
  - High levels of inflammation may increase ligamentous laxity (Afrin, 2021; Brock, 2021)
  - High levels of laxity may place stress on the vagus nerve, which regulates systemic inflammation and GI function, hence may contribute to MCAD
- Cervical instability is associated with increased dysautonomia/POTS
  - Compression to structures in the brainstem and cranial nerves (especially the vagus nerve) may increase dysautonomia (Takri, 2021)
- Sex hormones can alter ligamentous laxity (and MCAD)
  - Estrogen and relaxin increase ligamentous laxity (Em, 2015)



Understanding Instability

What Is Cervical Instability?

- Inability to control spinal movement within the 'neutral zone'
- Cervical stability is normally a combination of:
  - Passive structures, such as the disc, facet joints and ligaments
  - Muscles acting on or affecting the spine
  - Neurological system (brain and nerves) that controls the muscles
- People with hypermobility have stretchy passive structures
- BUT, what makes the spine unstable is failure of the muscles and nervous system to provide control

Potential Sources of Problems

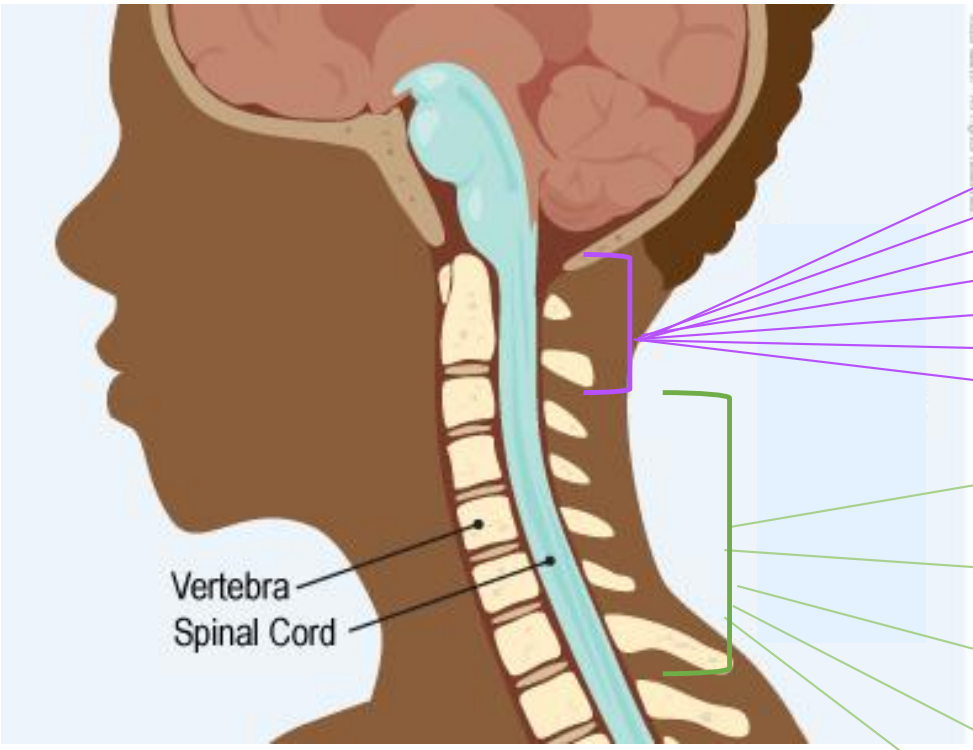

- Cord/brainstem compression
- Cranial nerve compression
- CSF blockage, Chiari
- Vertebral or carotid artery occlusion
- C1-C2 spinal nerves
- Joint capsules
- Trigger points and muscle spasm

- Cord compression
- CSF blockage
- Spinal nerves C3-C8
- Joint capsule, meniscoids
- Trigger points and muscle spasm

Musculoskeletal
Vascular
CNS

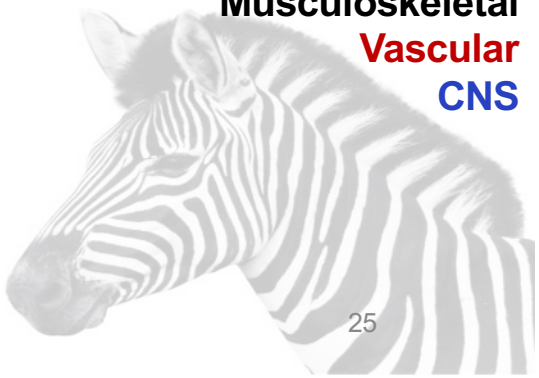

Symptoms of Cervical Instability

- Mostly musculoskeletal
  - Headaches (migraine-like, tension, occipital)
  - Aggravated by neck flexion (maybe extension)
  - Often associated with muscle spasm and trigger points
  - May include radiating nerve pain
- Moderate irritability neurological
  - Dizziness, “boat-rocking” instability, “bobble-head” sensation, fatigue holding head up, lump in throat
  - Dysautonomia is severe or difficult to manage, vagus nerve/GI symptoms,
  - Visual changes, voice changes, trouble swallowing, alertness may change with neck position
- High irritability neurological
  - Severe ”bobble-head” or “heavy-head”,
  - Severe/consistent lump in throat, trouble swallowing, choking sensation, trouble speaking, no gag reflex
  - Tingling in head/face, twitching eyelid, spasm in facial muscles, tongue asymmetry
  - Myoclonic (brief, intermittent) jerking, ‘dystonic episodes’ (muscles contracting repetitively or in writhing motions), especially after neck flexion/extension
  - Uncoordinated walking (not due to muscle/joint issues), full-body loss of coordination, loss of fine motor control in hands

Mostly Musculoskeletal

- Pain may be due to:
  - Muscle spasm or trigger point in muscles attempting to provide stability
    - Includes trigger point referral patterns and symptoms
  - Muscle spasm due to stress and tension
  - Joint pain from subluxing facet joints, pinched joint capsule, meniscoids
  - Nerve pain from compression on nerves
- Contributing factors:
  - Poor posture (includes sleep posture)
  - Poor body awareness (proprioception)
  - Poor motor control of stabilizing muscles
  - Stress & tension
  - Mast cell activation disorder (MCAD) or hormonal changes

- Pain may be mild or severe, may be intermittent or constant

HSD105: Posture & Joint Protection

Effects of Poor Posture

- Excessive forces on joints and muscles
- Muscle guarding & trigger points (TrP)
- Compression of nerves in the neck
- Compression of spinal cord structures

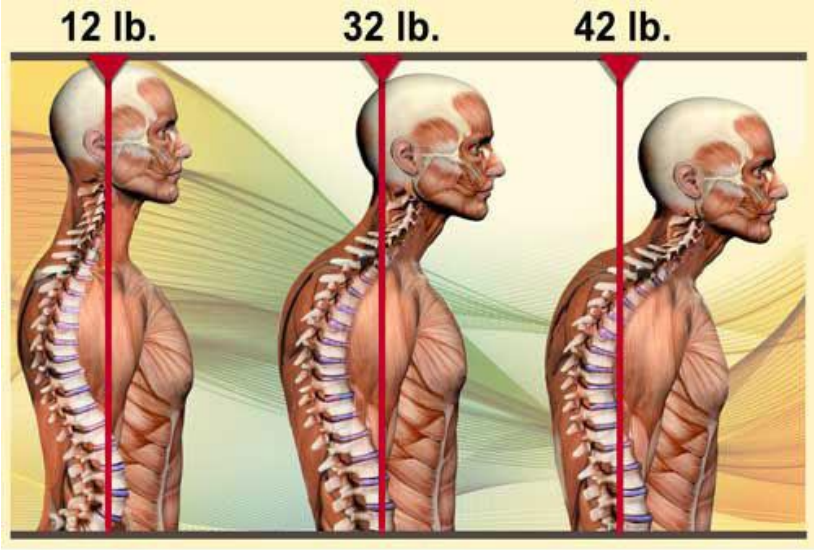

© 2010 www.erikdalton.com

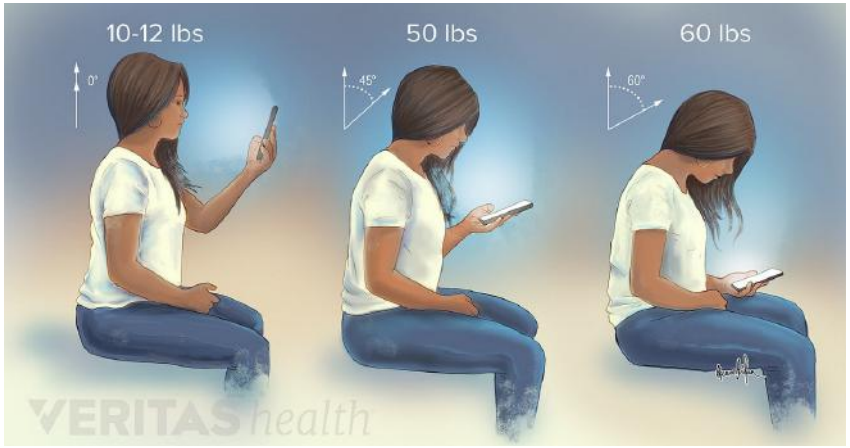

https://www.spine-health.com/conditions/neck-pain/text-neck-treatment-and-prevention

- Sleep posture is also important

HSD108: Headaches

Trigger Points (TrP)

- Created when superficial muscles are overworked because of:
  - Unstable joints
  - Poor posture (including sleep)
  - Poor body awareness (proprioception)
  - Weak/inactive deep neck stabilizing muscles

Resources on TrP:

- http://www.triggerpoints.net
- Valerie DeLaune, Pain Relief with Trigger Point Self-Help (2011)
- Valerie DeLaune, Trigger Point Therapy for Headache and Migraine: Your Self-Treatment Workbook for Pain Relief (2008)
- Richard Finn, Trigger Point Therapy Made Simple (2020)

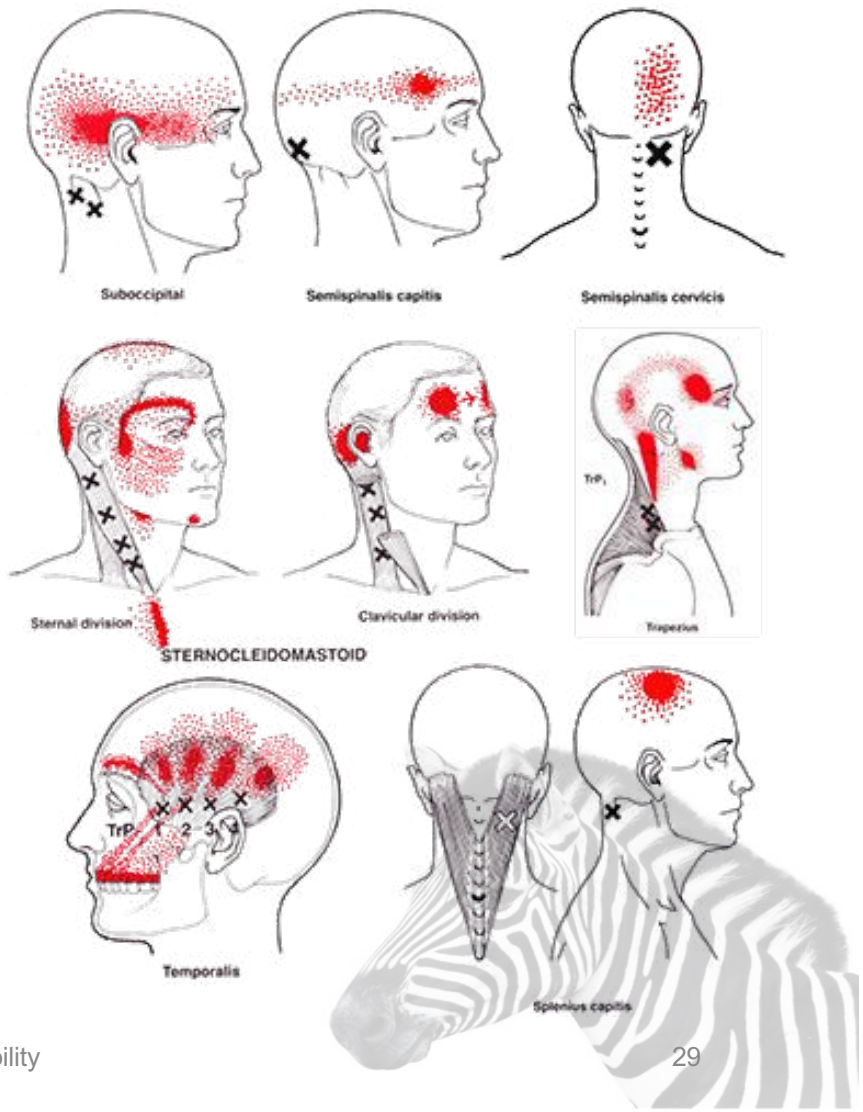

Joint Irritation or Subluxation

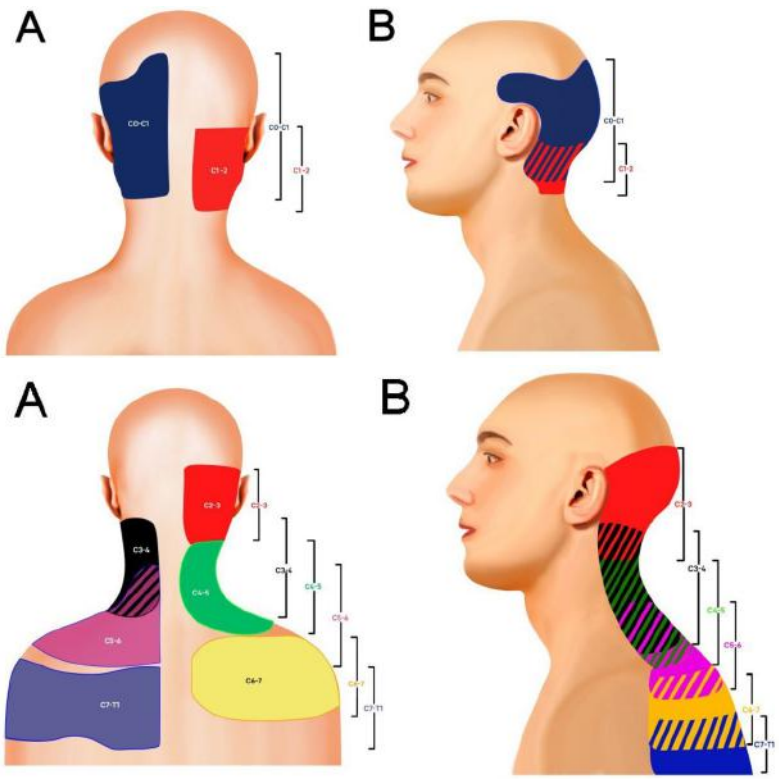

- Facet joints may be irritated by poor posture, instability (due to poor body awareness & poor motor control)
- Aggravated by specific postures, movement, being upright, muscle spasm (due to instability, stress, etc)
- Relieved by lying down, traction
  - (note: neck traction can be harmful for people with HSD, so only use if cleared by HSD-knowledgeable PT)
- Figures from Hurley, 2022

Peripheral Nerve-Related Headaches

- Often called ‘occipital neuralgia’
- Compression of suboccipital nerve in neck fascia
- Or compression of C1, C2, C3 nerve roots at the upper neck joints
  - Due to instability, poor posture, poor motor control
- May cause headaches, neck pain, numbness, tingling in scalp

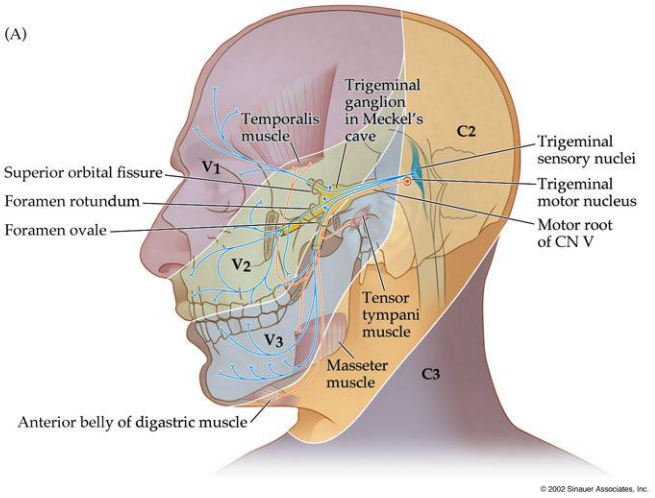

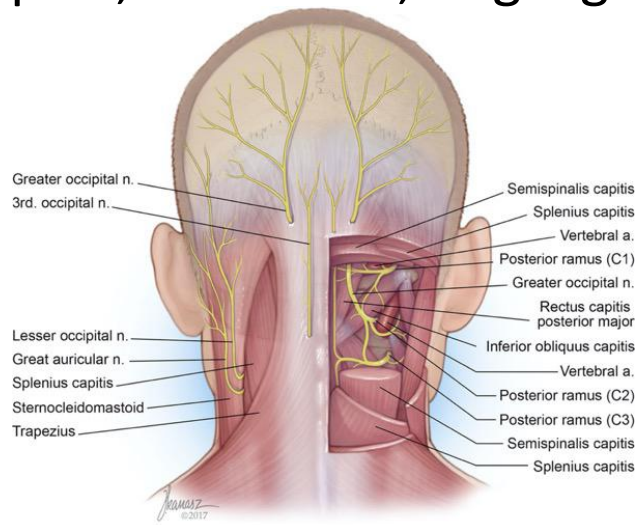

Lower Cervical Peripheral Nerves

- Instability in the lower cervical spine (C3-C7) can compress nerves
- Pain is typically 'radicular' – i.e., radiating down the arm
- May have numbness in specific regions, and weakness of specific muscles
- May be aggravated by poor posture
- May be relieved lying down, or by neck traction
  - (note: neck traction can be harmful for people with HSD, so only use if cleared by HSD-knowledgeable PT)

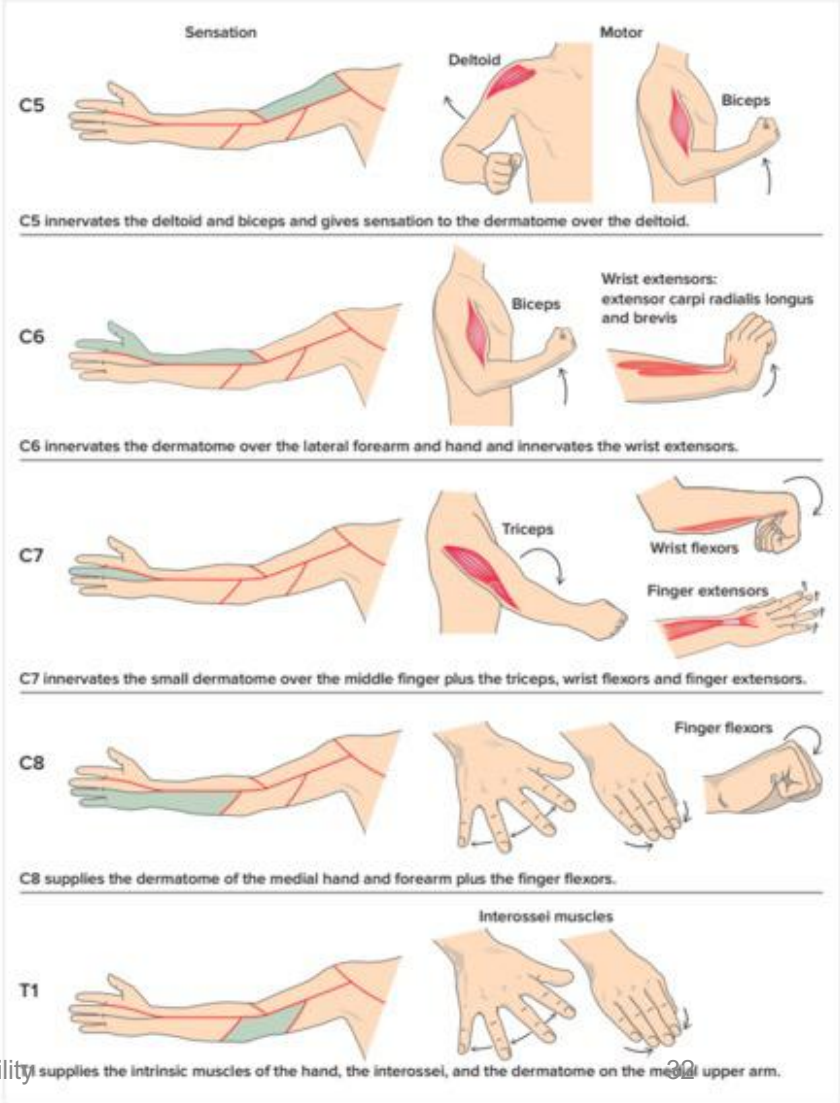

Questions?

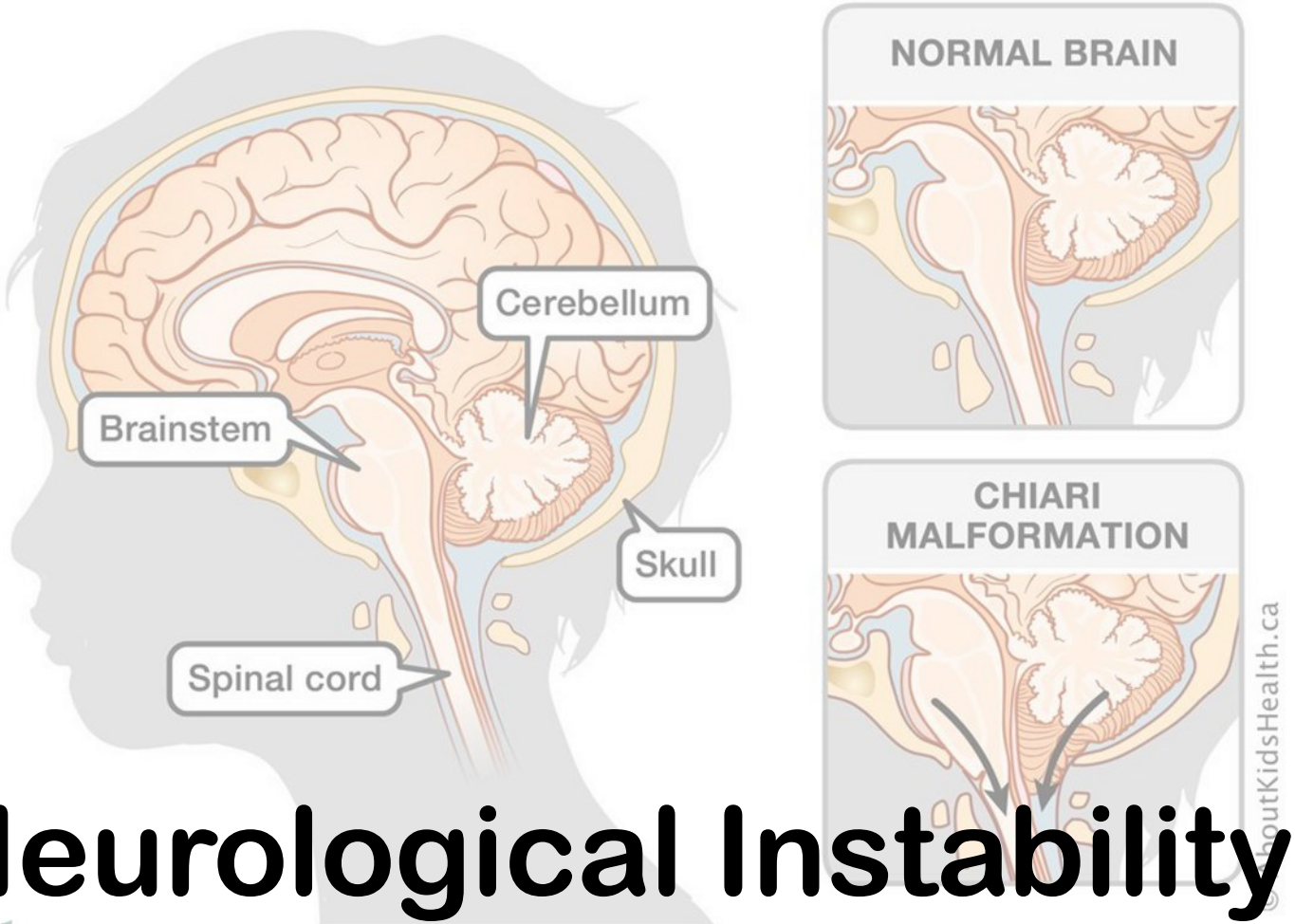

Neurological Instability

Potential Sources of Problems

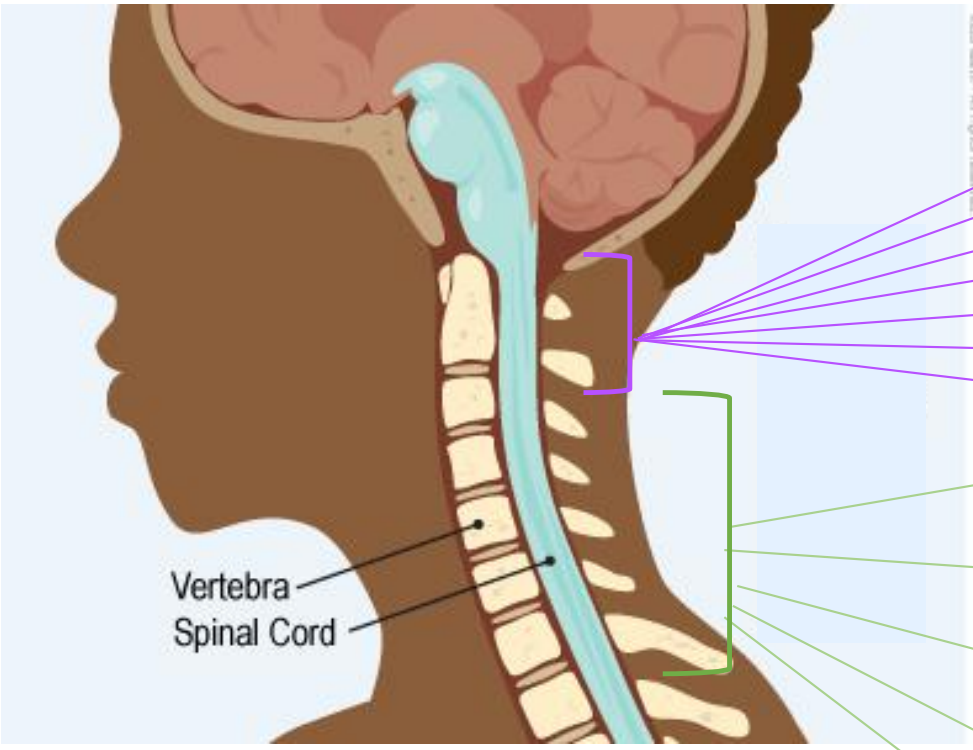

- Cord/brainstem compression
- Cranial nerve compression
- CSF blockage, Chiari
- Vertebral or carotid artery occlusion
- C1-C2 spinal nerves
- Joint capsules
- Trigger points and muscle spasm

- Cord compression
- CSF blockage
- Spinal nerves C3-C8
- Joint capsule, meniscoids
- Trigger points and muscle spasm

Musculoskeletal
Vascular
CNS

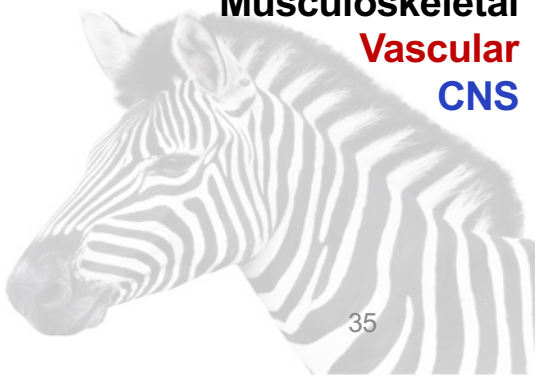

Caution!

- It can be scary to think that your central nervous system is affected
- Some of the neurological signs and symptoms of cervical instability (CI) are common in HSD independent of CI
  - That is: you may have these signs & symptoms but not have CI
  - You need to consult with a knowledgeable provider
- Some tests are not very Sensitive or Specific, and results may be misleading
- You cannot use the following information to diagnose the presence or absence of CI
- The following information is provided so that you can have a more educated conversation with your provider

How Accurate Are Tests?

Optional Technical Information

		Reality		
		Positive	Negative	
Test Result	Positive	(a) True +	False + (b)	a + b
	Negative	(c) False –	True – (d)	c + d
		a + c	b + d	

Sn = a/(a+c)

Sp = d/(b+d)

Sensitivity (Sn): Will the patient test (+) if she/he has the condition?

Specificity (Sp): Will the patient test (-) if she/he does not have the condition?

SnNOut: If **Sn** is high, a **N**egative test will rule **Out** the condition

SpPIn: if **Sp** is high, a **P**ositive test will rule **In** the condition

Sources of Neurological Involvement

- Compression of the spinal cord (myelopathy)
- Compression of the medulla/brainstem (cervical-medullary syndrome or Chiari)
- Compression or stretching of cranial nerves, especially III, VII, IX, X (dysautonomia, GI problems, facial abnormalities, etc.)
- Compression or stretching of arteries to the brain (dysautonomia or other dysfunctions in the brain due to inadequate blood flow)
- Compression or stretching of veins draining the brain (intracranial hypertension)

Cervical Myelopathy: Cord Compression

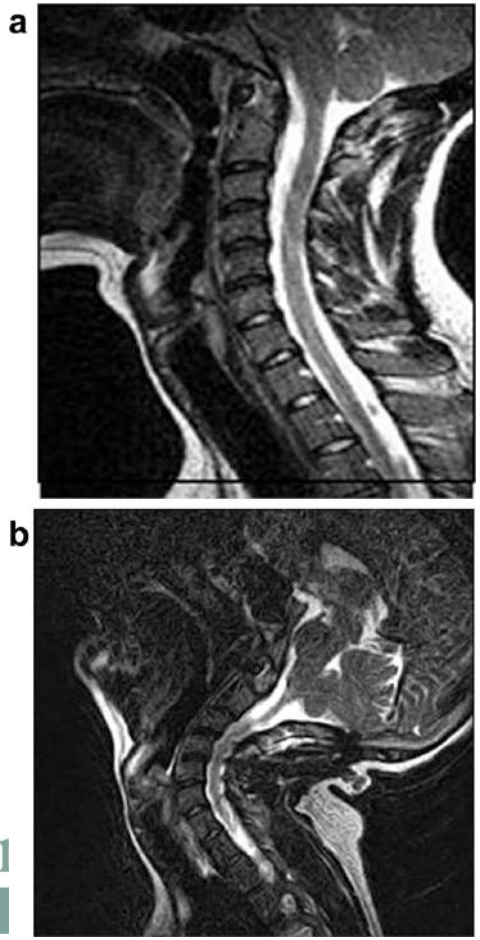

- May occur at any level of the cervical spine
- Compression is often not visible when the neck is in neutral (top picture), but can be seen in flexion or extension (bottom picture)
- This shows how imaging done with the neck in midrange might not show instability.
  - Imaging tests in neutral have low Sensitivity: negative test does NOT rule out the condition
- Appropriate tests:
  - Physical exam
  - MRI or dynamic motion x-ray in flexion/extension

Henderson, 2017

Signs & Symptoms of Myelopathy

- Symptoms (what you feel)
  - Neck flexion and/or extension changes symptoms other than pain
  - Feeling a lump in your throat, or trouble swallowing
  - Feeling clumsy in hands and feet, dropping things
  - Weakness in hands
- Signs (what we observe)
  - Abnormal reflexes: increased deep tendon reflexes (tendon tap), (+) Babinski, (+) Hoffman
  - ”Upper motor neuron” signs: difficulty with rapid alternating movements (e.g., tapping fingers, grip-release, etc.)
  - Abnormal walking pattern

Henderson, 2017

- *Items in grey are common in HSD, even when a person does not have cervical instability.*
- *Consequently, these are not very Specific: a positive finding does not provide proof that the condition exists.*

Upper Cervical Instability: CCI, AAI

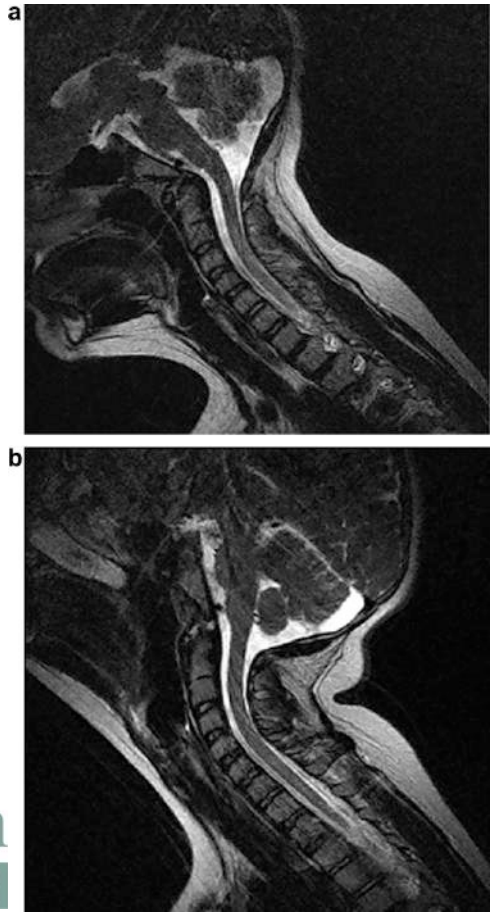

- Occurs at OA or AA joints
- Instability might occur only with neck motion
- Comparing flexion and extension views shows excessive front-back motion (CC or AA)
- Comparing rotation views shows excessive rotational motion (AA)
- Appropriate tests:
  - Upright MRI (supine/lying down is not Sensitive)
  - MRI or CT in flexion, extension, rotation
  - Dynamic x-ray in flexion/extension
  - CT scan in flexion, extension, rotation
  - Physical exam is helpful, but not conclusive
- Imaging lying down or with the neck in midline are generally not Sensitive, hence are not good diagnostic tests

Henderson, 2017

Signs & Symptoms of CCI/AAI

- Symptoms (what you feel)
  - Headache, usually at the base of the scull
  - Feeling like a “bobble head” or feeling too weak to hold your head up
  - Feeling a lump in your throat, or trouble swallowing
  - Vision changes
  - Dysautonomia that does not respond well to treatment
  - Vagus nerve symptoms: GI problems, nausea, vomiting, bloating, gastroparesis
  - Almost fainting (pre-syncopal episodes)
  - Dyspnea (difficulty breathing)
  - Dizziness & vertigo

- Signs (what we observe)
  - Changes in eye function (convergence, tracking or nystagmus)
  - Abnormal swallowing, loss of gag reflex, tongue asymmetry, uvula asymmetry, change in voice
  - Facial muscle twitching (especially the eyelid), altered sensation to the face
  - Abnormal reflexes: increased deep tendon reflexes (tendon tap), (+) Babinski, (+) Hoffman
  - ”Upper motor neuron” signs: difficulty with rapid alternating movements (e.g., tapping fingers, grip-release, etc.)
  - Dystonia (writhing muscles) or myoclonic jerking (twitching muscle spasm)
  - Fainting (syncope)
  - Symptoms (other than pain) increase with neck compression and decrease with neck distraction*
  - Rotation of C1 (only expert clinicians can feel this)
  - Abnormal walking pattern

Henderson, 2017

* Note: although patients may feel better with neck traction, traction is generally not considered a safe treatment for people with cervical instability

Chiari

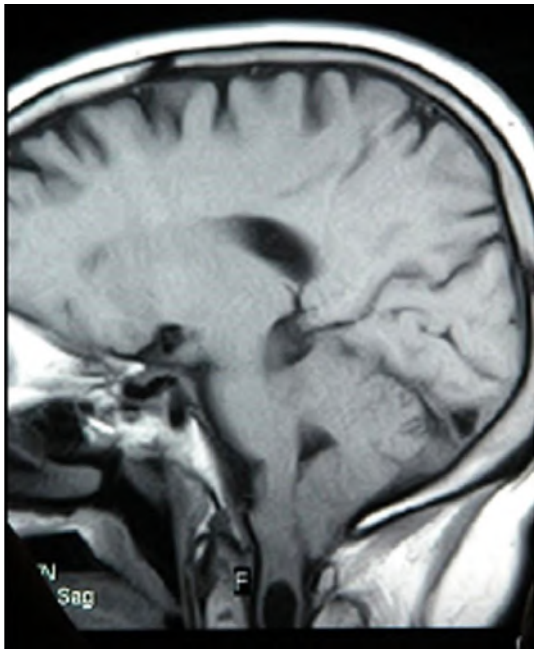

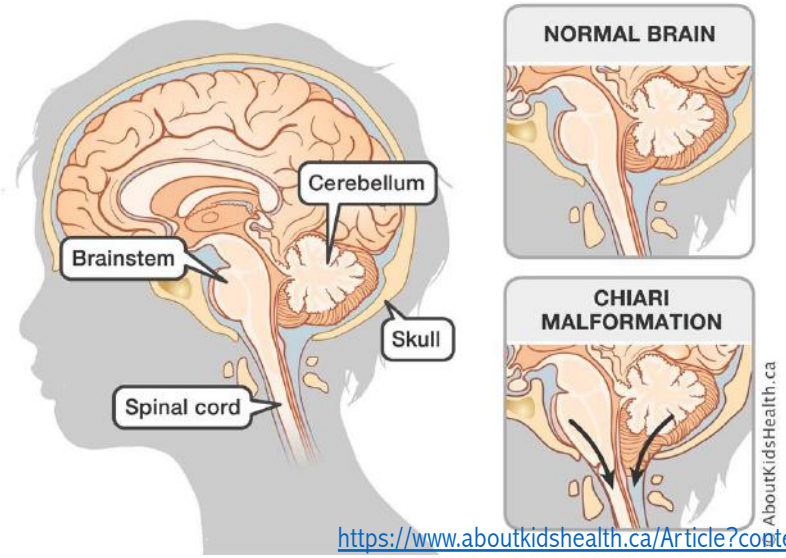

https://www.aboutkidshealth.ca/Article?contentid=853&language=English

- Brainstem and cerebellum sink down into the spinal canal
- Compresses brainstem and/or cerebellum
- Blocks flow of cerebrospinal fluid (CSF)
- Might be more likely when tethered cord exists
- Appropriate tests:
  - Upright MRI (supine/lying down is not Sensitive)
- Imaging lying down is not Sensitive, hence is not good diagnostic tests

Henderson, 2017

Signs & Symptoms of Chiari

- Symptoms (what you feel)
  - Headache that is worse with coughing, straining or yelling
  - Trigeminal neuralgia (picture below)
  - Dizziness

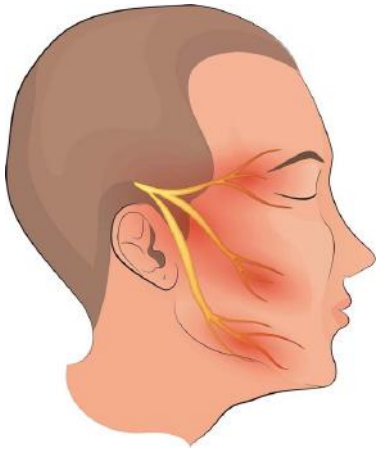

- Signs (what we observe)
  - Difficulty speaking
  - Hearing loss
  - Vestibular problems
  - Cranial nerve deficits
  - Sleep apnea
  - Dysautonomia
  - Coordination deficit
  - Abnormal walking pattern

Henderson, 2017

Vascular Compromise (Blocked Arteries)

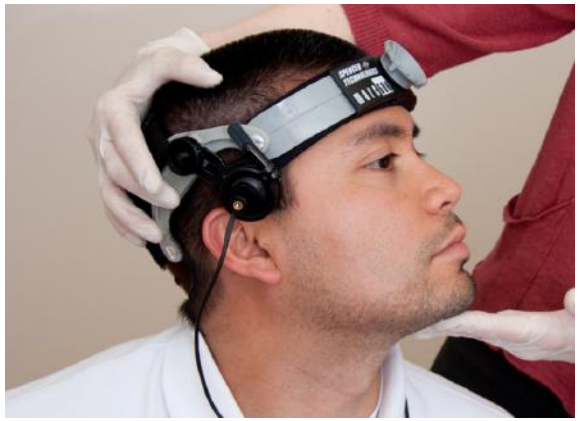

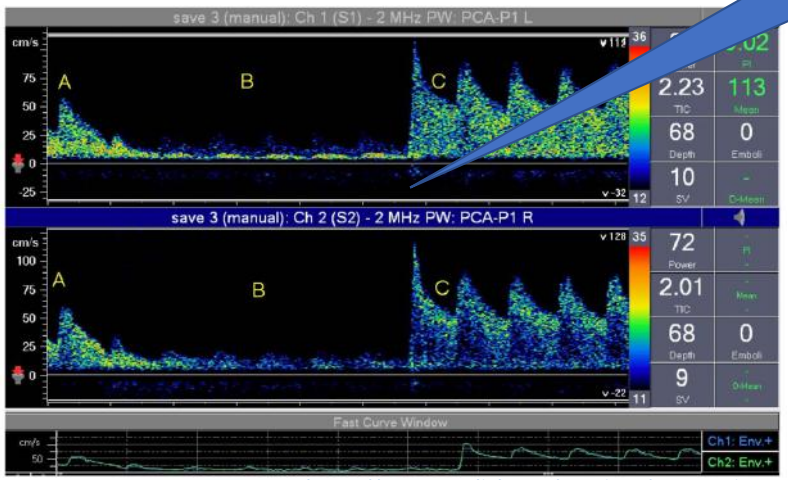

Blood flow in the vertebral artery can stop in neck rotation

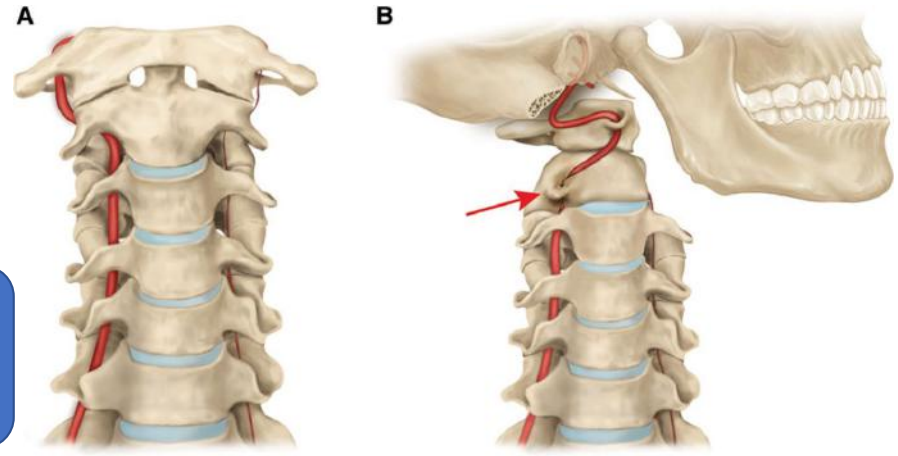

- The vertebral artery travels through holes in the ‘wings’ of the vertebrae
- Rotating the head stretches & compresses the vertebral artery
- The internal carotid artery is compressed by neck extension
- These can compromise blood flow to the brain

Test: Upright transcranial doppler of blood flow to the brain while moving the neck in different directions

- Note: MR or CT arthrogram in supine might not see a problem because the patient needs to be upright or have the neck rotated or tipped back to see. These are not Sensitive tests.

https://www.swedish.org/services/neuroscience-institute/our-services/cerebrovascular-center/our-services/swedish-vascular-ultrasound/vertebral-artery-compression

Signs & Symptoms of Arterial Compromise

- Symptoms (what you feel)
  - Pulsatile tinnitus
  - Scalp tenderness
  - Vagus nerve issues
  - Dry face
  - Posterior neck pain and temple pain
  - Brain-fog, trouble concentrating
  - Light-headed, dizzy
  - Depression (physiological)

- Signs (what we observe)
  - **Vertebral artery:**
    - Trouble swallowing or speaking (CN IX, X)
    - Nystagmus, double vision
    - Drop attacks (syncope, fainting)
    - Numbness in the face
    - Loss of coordination, unsteady walking
    - Arm or leg weakness
  - **Carotid artery**
    - Tongue/uvula (Ah) asymmetry (CN IX, X)
    - Drooping eyelid (Horner's syndrome), constricted pupil
    - Problems with eye movement (CN VI)
    - Neck swelling

Kerry, 2006

Compromised Veinous Flow

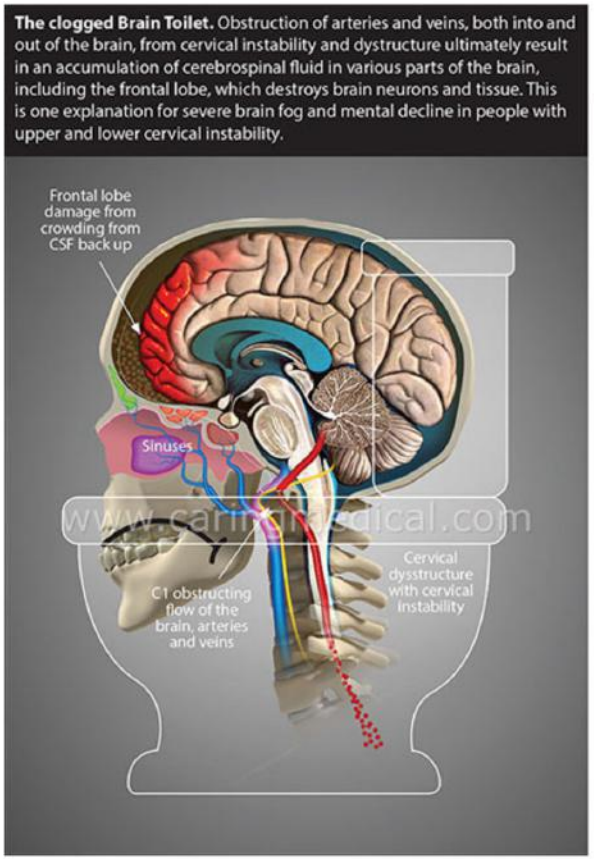

The clogged Brain Toilet. Obstruction of arteries and veins, both into and out of the brain, from cervical instability and dystructure ultimately result in an accumulation of cerebrospinal fluid in various parts of the brain, including the frontal lobe, which destroys brain neurons and tissue. This is one explanation for severe brain fog and mental decline in people with upper and lower cervical instability.

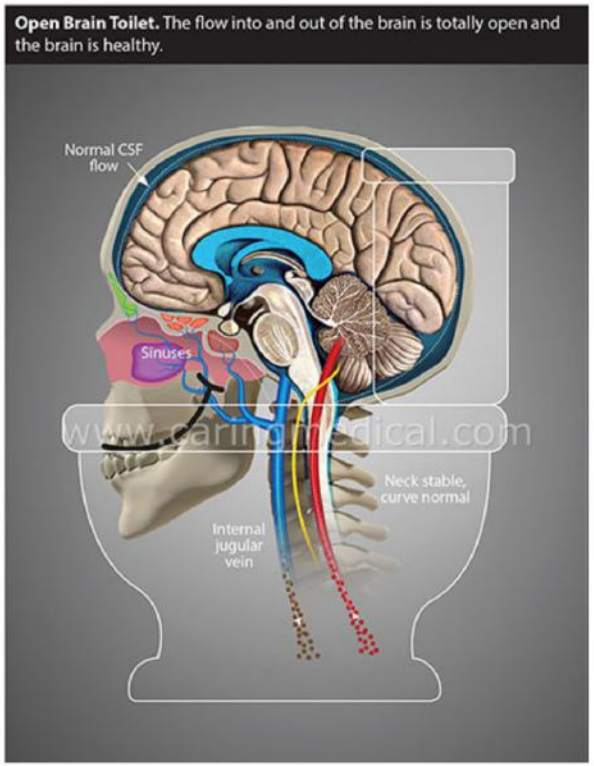

Open Brain Toilet. The flow into and out of the brain is totally open and the brain is healthy.

- The brain needs to flush out toxins through either blood flow in the veins, or through cerebrospinal fluid (CFS)
- Cervical instability can interfere with veinous and/or CSF flow
- Intracranial hypertension may result

https://www.caringmedical.com/prolotherapy-news/cervical-spine-instability-pinches-arteries-disrupts-impedes-retards-blood-flow-brain/

Vascular Compromise: Internal Jugular

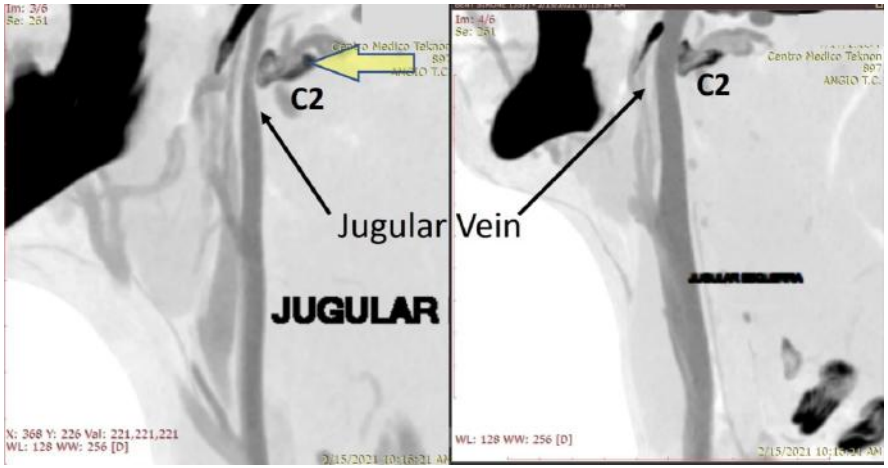

- Right picture shows normal internal jugular
- Left picture shows compression of jugular

- Occurs if there is excessive rotation of C1 on C2, which is common in HSD
- Aggravated by neck rotation or extension
- May also occur in Eagle Syndrome, where a long styloid process may compress the jugular
- May result in intracranial hypertension (increased pressure on the brain)
- Tested by ultrasound or doppler of the neck

Li, 2019; Ding, 2019; Mooney, 2020

Signs & Symptoms of Jugular Compression

- Symptoms (what you feel)
  - Noises heard in the head,
  - Tinnitus (ringing in the ears),
  - Headaches,
  - Hearing loss
  - Neck discomfort, stiffness,
  - Double or blurry vision
  - Nausea or vomiting
  - Insomnia,
  - Transient amnesia

- Signs (what we observe)
  - Hearing loss
  - Loss of visual field
  - Possible intracranial hypertension

Li, 2019; Ding, 2019; Mooney, 2020

Potential Sources of Problems

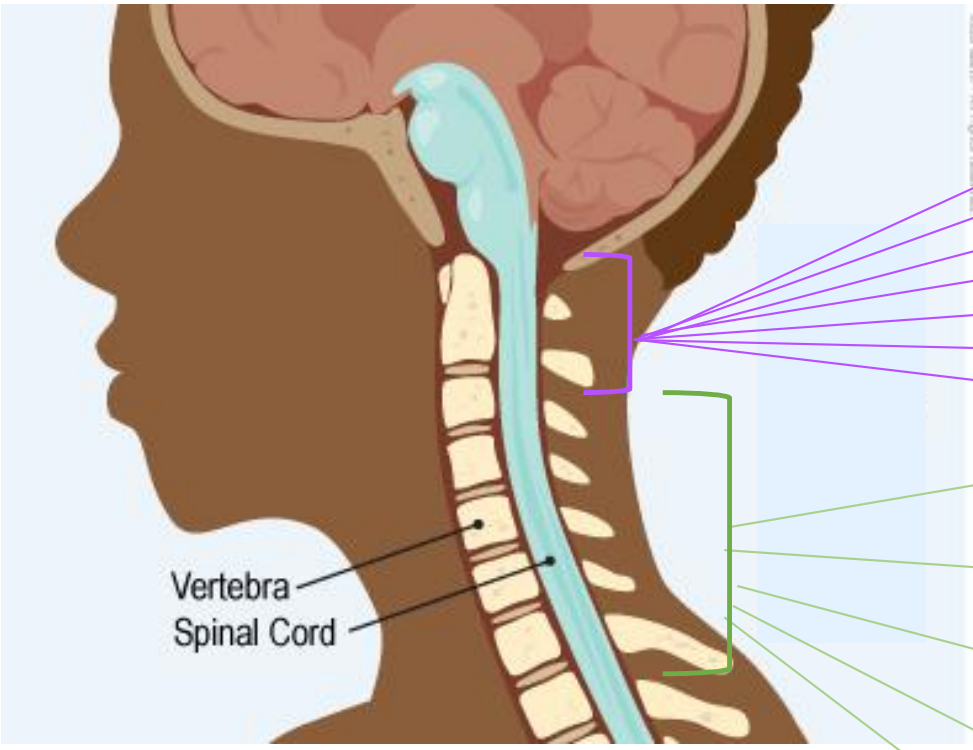

- Cord/brainstem compression
- Cranial nerve compression
- CSF blockage, Chiari
- Vertebral or carotid artery occlusion
- C1-C2 spinal nerves
- Joint capsules
- Trigger points and muscle spasm

- Cord compression
- CSF blockage
- Spinal nerves C3-C8
- Joint capsule, meniscoids
- Trigger points and muscle spasm

Musculoskeletal
Vascular
CNS

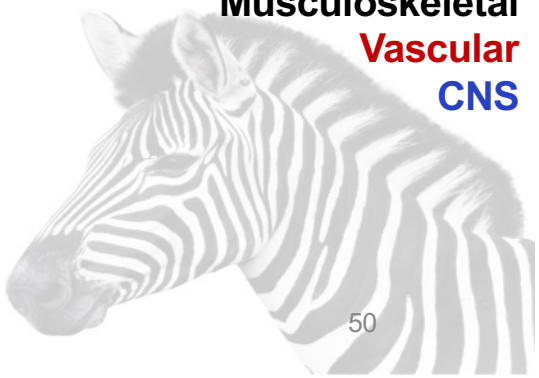

In Summary…

- Cervical instability is complicated!
- Instability may impact many different structures, which can lead to a variety of confusing signs & symptoms
- Signs and symptoms may vary over time based on
  - Your overall hypermobility (due to hormones or MCAD)
  - Your fitness level and the control and strength of your neck/body stabilizers
  - Your activities and postures
- Providers need to consider the different structures that might be causing your signs & symptoms
- Many standard tests (e.g. MRI lying down, neck neutral) are not very Sensitive, which means that a negative test does not rule out the condition

Resources

- Ehlers-Danlos Society
  - https://www.ehlers-danlos.com/2017-eds-classification-non-experts/ For non-experts
  - https://www.ehlers-danlos.com/2017-eds-international-classification/ (technical)
- The following site has useful information about cervical instability. The site recommends prolotherapy (injections). I can neither support nor criticize prolotherapy. But the site has a lot of good information. https://www.caringmedical.com/conditions/prolotherapy-neck-pain-cervical-instability/
- Neurosurgical EDS specialist MDs
  - Dr. Fraser Henderson (Baltimore, MD): https://www.metropolitanneurosurgery.org/dr-fraser-henderson/
  - Dr. Paulo Bolognese (NYC): https://www.southnassau.org/sn/chiari-eds?srcaud=Main
    - YouTube: https://youtu.be/MsYDA3SXTkg
  - Dr. Sunil Patel (Charleston, NC): https://musc.bcst.md/participant/sunil-patel-m-d
- PTs who specialize in cervical instability
  - Susan Chalela: (Charleston, NC)
  - Wendy Wagner (Chicago, IL): www.wendy4therapy.com
  - Patricia Stott (Aurora, CO): www.elevationwellness.co
  - Heather Purdin (Portland, OR): https://goodhealthphysicaltherapy.com



Journal Article References

- Afrin LB. Some cases of hypermobile Ehlers-Danlos syndrome may be rooted in mast cell activation syndrome. *Am J Med Genet C Semin Med Genet*. Dec 2021;187(4):466-472.
- Brock I, Chopra P, Maiteland A, Francomano C. Frequency and co-occurrence of comorbidities in the Ehlers-Danlos syndromes. April 2021. Molecular Genetics and Metabolism 132:S194.
- Celenay ST, Akbayrak T, Kaya DO. A Comparison of the Effects of Stabilization Exercises Plus Manual Therapy to Those of Stabilization Exercises Alone in Patients With Nonspecific Mechanical Neck Pain: A Randomized Clinical Trial. J Orthop Sports Phys Ther. 2016 Feb;46(2):44-55.
- Cook C, Brown C, Isaacs R, Roman M, Davis S, Richardson W. Clustered clinical findings for diagnosis of cervical spine myelopathy. J Man Manip Ther. 2010 Dec;18(4):175-80.
- Ding JY, Zhou D, Pan LQ, et al. Cervical spondylotic internal jugular venous compression syndrome. *CNS Neurosci Ther*. 2020;26(1):47-54.
- Em S, Oktayoglu P, Bozkurt M, Caglayan M, Karakoc M, Ucar D, Verim S, Yildiz I, Sariyildiz MA, Evliyaoglu O, Nas K. Serum relaxin levels in benign hypermobility syndrome. J Back Musculoskelet Rehabil. 2015;28(3):473-9.
- Finucane LM, Downie A, Mercer C, et al. International Framework for Red Flags for Potential Serious Spinal Pathologies. *J Orthop Sports Phys Ther*. Jul 2020;50(7):350-372.
- Gibbons SGT, Comerford MJ. Strength versus stability: Part 1: Concept and terms. *Orthopaedic Division Review.* 2001;March / April: 21-27.
- Hurley RW, Adams MCB, Barad M, Bhaskar A, Bhatia A, Chadwick A, Deer TR, Hah J, Hooten WM, Kissoon NR, Lee DW, Mccormick Z, Moon JY, Narouze S, Provenzano DA, Schneider BJ, van Eerd M, Van Zundert J, Wallace MS, Wilson SM, Zhao Z, Cohen SP. Consensus practice guidelines on interventions for cervical spine (facet) joint pain from a multispecialty international working group. Reg Anesth Pain Med. 2022 Jan;47(1):3-59.
- Kerry R, Taylor AJ, Mitchell J, McCarthy C. Cervical arterial dysfunction and manual therapy: a critical literature review to inform professional practice. *Man Ther*. Aug 2008;13(4):278-88.
- Li M, Su C, Fan C, Chan CC, Bai C, Meng R. Internal jugular vein stenosis induced by tortuous internal carotid artery compression: two case reports and literature review. J Int Med Res. 2019 Aug;47(8):3926-3933.
- Li Q, Xie P, Yang WS, Yan B, Davis S, Caplan LR. Vertebral Artery Compression Syndrome. *Front Neurol*. 2019;10:1075. doi:10.3389/fneur.2019.01075
- McCormick JR, Sama AJ, Schiller NC, Butler AJ, Donnally CJ, 3rd. Cervical Spondylotic Myelopathy: A Guide to Diagnosis and Management. *J Am Board Fam Med*. Mar-Apr 2020;33(2):303-313. Mooney J, Lepard J, Akbari SHA, Johnston JM. Styloidogenic jugular venous compression syndrome: a case report and review of the literature. Childs Nerv Syst. 2020 Dec;36(12):3135-3139.
- Takri T, Mathew RR, Sivadasan A, Raju K, Karuppusami R, Mariappan R. The Utility of COMPASS-31 Questionnaire to Predict Autonomic Dysfunction in Patients With Cervical/Upper Thoracic Compressive Myelopathy. *J Neurosurg Anesthesiol*. Dec 7 2021.

Thank You!

Questions?

Remember – I CANNOT diagnose you!